

Case Report



Auditory Neuropathy Spectrum Disorder in Brown-Vialetto-Van Laere Syndrome

Hossein Talebi*

Department of Audiology, School of Rehabilitation Sciences, Isfahan University of Medical Sciences, Isfahan, Iran



Citation: Talebi H. Auditory Neuropathy Spectrum Disorder in Brown-Vialetto-Van Laere Syndrome. Aud Vestib Res. 2022;31(3):238-42.
<https://doi.org/10.18502/avr.v31i3.9874>

Highlights

- Brown-Vialetto-Van Laere syndrome (BVVL) is a rare progressive neurological disorder
- BVVL shows worsening of hearing problems due to auditory neuropathy spectrum disorder

Article info:

Received: 02 Feb 2022

Revised: 13 Mar 2022

Accepted: 03 Apr 2022

* Corresponding Author:

Department of Audiology, School of Rehabilitation Sciences, Isfahan University of Medical Sciences, Isfahan, Iran.
ht6023@gmail.com

ABSTRACT

Background and Aim: This study shows the clinical symptoms pertinent to auditory neuropathy spectrum disorder (ANSD) for a 16-year-old girl with Brown-Vialetto-Van Laere Syndrome (BVVL). The results have been followed for six years between 2015 and 2021.

The Case: In the present study, auditory test battery including tympanometry, acoustic reflex, pure tone audiometry, transient evoked otoacoustic emissions and auditory brainstem response were utilized and repeated three times during six years.

Conclusion: In the first session, the results revealed bilaterally normal transient evoked otoacoustic emissions, absent acoustic reflexes (ipsilateral and contralateral), mild to moderate low tone loss in the pure tone audiometry, no auditory brain stem responses at high stimulus intensities and different polarities and present cochlear microphonic component in single polarities. In the second session, pure tone audiometry showed slight to mild high tone loss but the other tests demonstrated their same results. In the final session, the latter results were repeated. In this comprehensive follow up study, the patient with BVVL demonstrated clinical symptoms of auditory neuropathy spectrum disorder in which auditory system showed an impairment in the auditory temporal synchronization and encoding.

Keywords: Brown-Vialetto-Van Laere syndrome; auditory neuropathy spectrum disorder; auditory brainstem response; pure tone audiometry



Introduction

A 10-year-old girl on the first admission referred with her parents from a child neurologist in 2015 to assess auditory function and evaluate auditory responses. She was the only child of her parents and was born full term in hospital. There were no risk factors including hypoxia, neonatal intensive care unit hospitalization, cytomegalovirus and no other problems related to development of central nervous system during first six years of life. By contrast, after this period of time and due to the incidence of problems in her face appearance and behavior, neurological examination showed that she developed bilateral cranial polyneuropathy, bilateral ptosis and esotropia, inability to laugh, blow and suck. Moreover, the patient was unable to stick out her tongue. Gag reflex was weak, but visual and auditory functions seemed to be normal [1]. Initial diagnostic tests including brain magnetic resonance imaging, electromyography, nerve conduction velocity, and acetylcholine antibody studies were conducted to provide more detail information about the progressive disease. At the first time, differential diagnoses included myasthenia gravis, Brown-Vialetto-Van Laere Syndrome (BVVL), polyneuritis cranialis, neurosarcoidosis, and malignant infiltration of the cranial nerve roots. After four months, no abnormalities were found on repeat brain MRI. However, electromyography and nerve conduction velocity showed axonal injury of bilateral seventh nerves. More significantly, the auditory brainstem response (ABR) revealed no responses at high intensities showing an involvement of eighth nerve bilaterally. In addition, EMG demonstrated neurogenic changes in the tongue and facial muscles [1]. The results of the clinical and electrophysiological studies were indicative polyneuritis

cranialis and the child received medications including intravenous immunoglobulin in the first two years after onset of illness and daily riboflavin until now. Despite the mentioned treatment, she experienced worsening of symptoms in the following years. Due to this condition, genetic study was performed and confirmed BVVL. It is indicated that the prevalence of this syndrome is very low and only fifty-eight patients in just over a century. Approximately half of all cases are sporadic [1]. The majority of familial cases demonstrate autosomal recessive inheritance, although autosomal dominant or X-linked inheritance has been suggested in a few families. The female to male ratio is approximately 3:1 in reported cases [1]. 6 years later in 2021, the patient showed masked face, no ABR in both ears, bilateral ptosis, reduced gag reflex and blurred speech. The patient suffered from perception difficulties of speech and hearing in noisy situations. Also, she suffered from depression due to her disabilities. In the present study, the patient was evaluated by complete auditory tests during six years to reveal her auditory problems objectively and behaviorally.

Audiological assessments

In the present study, a complete case history focused on hearing problems was taken from the child and her parents in the first session of auditory system evaluation. The collected key information provided a good profile of child's problems in hearing perception of speech sounds in noisy situations such as school classrooms. In order to evaluate her auditory system, auditory test battery including tympanometry, acoustic reflex, pure tone audiometry, transient-evoked otoacoustic emissions (TEOAEs) and click-evoked ABR was utilized. In the first session back in 2015, otoscopic inspection showed normal condition of the external ear canal and

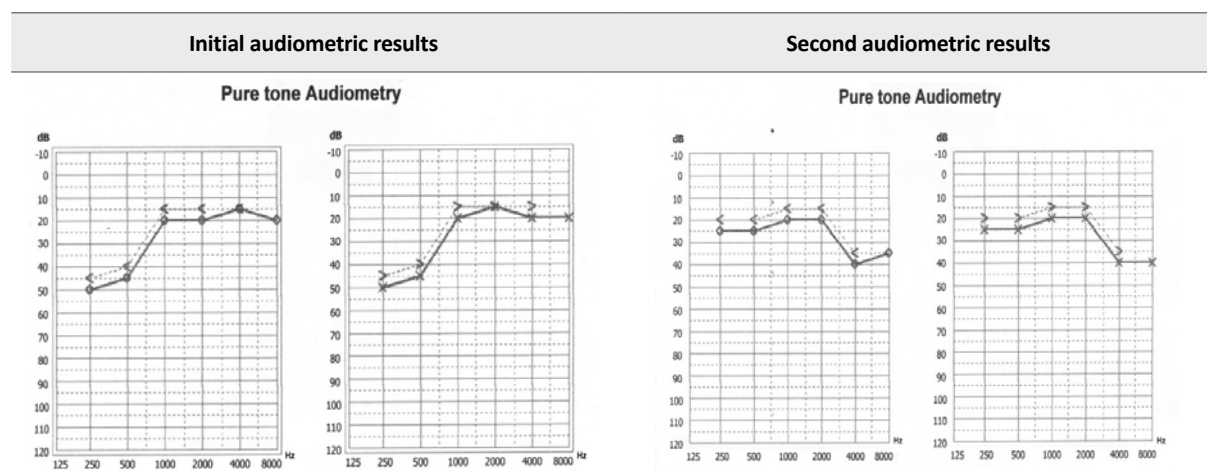


Figure 1. The initial (first session) and second results (second session) of pure tone audiometry: mild to moderate low tone loss changed to slight to mild high tone loss in both ears.

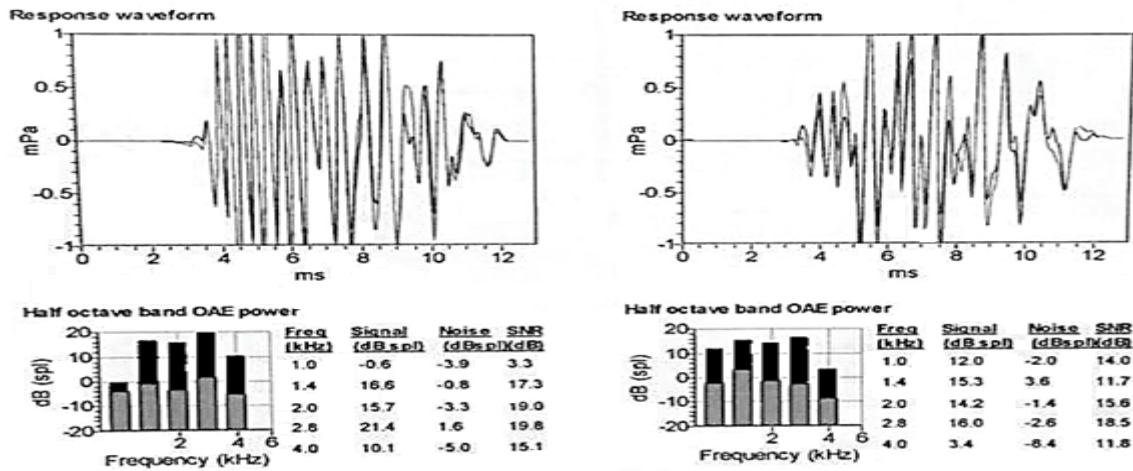


Figure 2. Transient-evoked otoacoustic emissions in both ears. The amplitude of responses was identified by dark color.

tympanic membrane. Immittance acoustic revealed normal tympanograms (type An) and absent ipsilateral and contralateral acoustic reflexes bilaterally. Pure tone audiometry indicated bilaterally mild to moderate low tone loss with very good score (100%) in word recognition test in an acoustic chamber. Three years later (second session), the audiometric results revealed clinically normal thresholds in low frequencies but slight to mild sensory-neural hearing loss in high frequencies (Figure

1). TEOAE demonstrated good signal to noise ratios in different frequencies indicating normal function of outer hair cells in both ears (Figure 2). The click-evoked ABR which can be conducted objectively to assess auditory nervous system in both ears illustrated no responses (waves I, III and V) at high stimulus intensity (100 dB nHL) and different polarities (rarefaction, condensation and alternation). However, the results showed bilaterally cochlear microphonic potential for rarefaction and con-

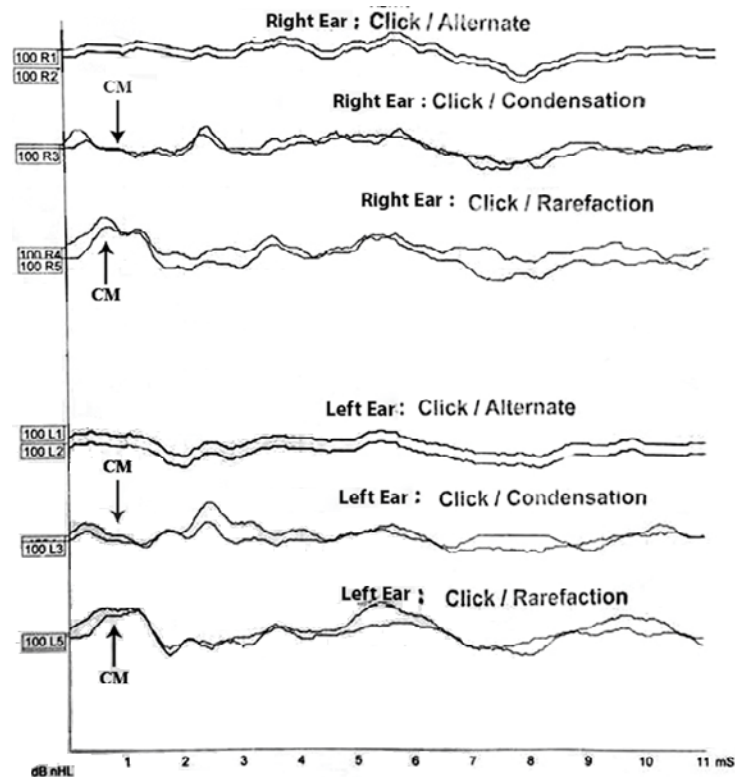


Figure 3. No auditory brainstem responses (waves I, III and V) at high stimulus intensity and different polarities in both ears. Cochlear microphonic component could be distinguished in single polarities.

densation polarities (Figure 3). The other assessments showed the same. Finally, in final session, all of the tests were repeated and the results confirmed the latter ones.

Discussion

Brown-Vialetto-Van Laere Syndrome is a rare progressive neurological disorder with worsening of symptoms in the following years of life [1]. The clear symptoms are progressive pontobulbar palsy associated with bilateral ptosis, reduced gag reflex, bilateral hearing disorder and tongue atrophy [2]. The age of onset could be from infancy up to as late as 30 years old [1]. In this study, auditory test battery including behavioral, physiologic and electrophysiologic auditory tests was utilized to demonstrate function of auditory system in a child with BVVL. Interestingly, pure tone audiometry showed mild to moderate low tone loss bilaterally in the first session changed to normal thresholds in the low frequency and slight to mild high tone loss in the second session. The other significant result was no auditory brainstem responses bilaterally at high stimulus intensity and different polarities in three sessions. By contrast, TEOAEs and cochlear microphonic responses were present and repeated in this case. Overall, these interesting results showed auditory neuropathy spectrum disorder (ANSD) indicating possible problems in auditory temporal encoding [3, 4]. It is believed that sound transduction and speech perception need to a high level of synchronized activity. Disturbance to auditory nerve synchrony interferes with the temporal coding of sound, which is the most important factor in speech perception [5]. It is reported that most of the patients with auditory neuropathy/auditory dys-synchrony show hearing problems and report difficulties in hearing and speech perception in noisy situations [6, 7]. In this study, the child with BVVL showed clear auditory perception difficulties due to ANSD. Based on the results, it is presumed that the auditory system can show different behaviors to different acoustic stimuli; pure tones can produce normal or nearly normal responses but transient stimuli such as click can show no responses in cases with BVVL. This finding could be related to abnormal synchronization in patients with ANSD [6, 7]. In fact, many patients with this disorder may report misunderstanding in auditory environments with abrupt acoustic changes (especially in time) e.g. situations with competing stimuli and educational classrooms. To survey and monitor the severity of central auditory processing involvement in these cases, more behavioral (speech in noise test) and electrophysiological auditory assessments (auditory evoked potentials using complex auditory stimuli including speech signals) should be conducted.

Conclusion

To sum up, it is claimed that this study is one of the first reports of monitoring auditory responses in patients with Brown-Vialetto-Van Laere Syndrome during a 6-year period after initial diagnosis. The results of this study emphasized on different types of auditory system responses to different stimuli due to auditory neuropathy spectrum disorder.

Ethical Considerations

Compliance with ethical guidelines

This study was carried out in accordance with the Helsinki Declaration and the written informed consent was obtained from her parents.

Funding

This research did not receive any grant from funding agencies in the public, commercial, or non-profit sectors.

Authors' contributions

HT: The study design, data collection, analysis and interpretation of results, drafting the manuscript.

Conflict of interest

The author does not have any financial or other interests relating to the study.

Acknowledgements

I would like to thank the case and her parents (especially her mother) to participate in this study and share their information and experiences.

References

- [1] Sathasivam S. Brown-Vialetto-Van Laere syndrome. *Orphanet J Rare Dis*. 2008;3:9.2. [DOI:10.1186/1750-1172-3-9]
- [2] Chandran R, Alexander M, Naina P, Balraj A. Auditory neuropathy spectrum disorder with Brown-Vialetto-Van Laere syndrome: Challenges in hearing rehabilitation. *J Laryngol Otol*. 2015;129(5):504-8. [DOI:10.1017/S0022215114003375]
- [3] Kirkim G, Serbetcioglu B, Erdag TK, Ceryan K. The frequency of auditory neuropathy detected by universal newborn hearing screening program. *Int J Pediatr Otorhinolaryngol*. 2008;72(10):1461-9. [DOI:10.1016/j.ijporl.2008.06.010]

- [4] Sanyelbhaa Talaat H, Hasn Kabel A, Samy H, Elbadry M. Prevalence of auditory neuropathy (AN) among infants and young children with severe to profound hearing loss. *Int J Pediatr Otorhinolaryngol.* 2009;73(7):937-9. [DOI:10.1016/j.ijporl.2009.03.009]
- [5] Trussell LO. Synaptic mechanisms for coding timing in auditory neurons. *Annu Rev Physiol.* 1999;61:477-96. [DOI:10.1146/annurev.physiol.61.1.477]
- [6] Zeng FG, Kong YY, Michalewski HJ, Starr A. Perceptual consequences of disrupted auditory nerve activity. *J Neurophysiol.* 2005;93(6):3050-63.] [DOI:10.1152/jn.00985.2004]
- [7] Zeng FG, Oba S, Garde S, Sininger Y, Starr A. Temporal and speech processing deficits in auditory neuropathy. *Neuroreport.* 1999;10(16):3429-35. [DOI:10.1097/00001756-199911080-00031]