

CASE REPORT

A case report of cochlear implantation in patients with osteopetrosis: surgical approaches and auditory results

Masoud Motasaddi Zarandy^{1,2}, Hakima Abdullah¹, Mina Motasaddi Zarandy³, Mohammadreza Firouzifar^{1*}, Farzad Moubedshahi⁴

¹- Otorhinolaryngology Research Center, Tehran University of Medical Sciences, Tehran, Iran

²- Department of Otolaryngology, Head and Neck Surgery, Amir A'lam Hospital, Tehran University of Medical Sciences, Tehran, Iran

³- Department of Neurology and Neurosurgery, Montreal Neurological Institute, McGill University, Montreal, Canada

⁴- Amir A'lam Cochlear Implant Center, Tehran University of Medical Sciences, Tehran, Iran

Received: 21 Oct 2020, Revised: 18 Nov 2020, Accepted: 28 Nov 2020, Published: 15 Jan 2021

Abstract

Background: Osteopetrosis (OP) is a rare disease of the skeletal system that can be associated with complications such as bone fracture, nerve dysfunction and deafness due to increased bone density and reduced bone quality. In this regard and due to the challenge that it can cause for cochlear implantation (CI), in this study we aimed to report CI conducted on two patients with OP in Iran.

The Case: Patients were two women diagnosed with OP and bilateral sensorineural hearing loss (SNHL) who underwent CI in the right ear. Pre-operative PTA showed a hearing threshold decrease of more than 100 dB in both patients. A standard cochleostomy was performed in one patient and endoscopic surgery in the other patient through the external ear canal. One month after surgery, the hearing threshold improved by 60–90 dB in both patients. No facial nerve palsy or implant extrusion/migration was observed after surgery.

Conclusion: Although technically challenging, CI seems to be a safe and effective method to improve the SNHL in patients with OP. The path

for electrode insertion should be tailored to meet the conditions and anatomy of patients.

Keywords: Cochlear implantation; osteopetrosis; sensorineural hearing loss

Citation: Motasaddi Zarandy M, Abdullah H, Motasaddi Zarandy M, Firouzifar M, Moubedshahi F. A case report of cochlear implantation in patients with osteopetrosis: surgical approaches and auditory results. *Aud Vestib Res.* 2021;30(1):56-61.

Introduction

Osteopetrosis (OP) is a rare disease. It is inherited as autosomal dominant, autosomal recessive, or X-linked. In the autosomal recessive pattern, OP has a prevalence of 1 in 250,000 births, while its prevalence is 1 in 20,000 births in the autosomal dominant pattern [1]. Osteoclast dysfunction in OP is the main pathology that increases bone formation and decreases bone resorption; therefore, an increase in bone density occurs. The patients with OP have many problems, especially in the skull base region, such as occlusion of the skull foramina which results in nerve compression and a variety of hearing loss patterns (conductive, sensorineural and mixed hearing loss). Although cochlear

* **Corresponding author:** Otorhinolaryngology Research Center, Tehran University of Medical Sciences, Tehran, 1145765111, Iran. Tel: 009821-66703037, E-mail: mrfirouzifar@sina.tums.ac.ir



Fig. 1. The second case with bilateral sensorineural hearing loss caused by osteopetrosis that was treated with cochlear implantation using modified technique.

implantation (CI) may help OP patients, its technical difficulty and unknown results cause the surgeon reconsider his/her decision. There is only a case report of using CI on OP patients [2]. In this study, we report our experience in using CI and its results on patients with OP.

Case presentation

First patient

First patient was a 47-year-old woman who suffered from gradual hearing loss in both ears for 4 years, which led to profound hearing loss. The patient had normal speech, lip-reading ability, and a good voice. She was using hearing aids since the age of 25. Her mother also had hearing loss at higher age. Anosmia, intense tinnitus, and deformities in the neck, fingers and knees were evident in the patient. Under X-ray imaging, increased bone density was evident in the base of the skull, temporal bone, pelvis, lumbar spine, knees and hands. Acoustic impedance test showed a flat tympanometry. In the pure tone audiometry (PTA), the hearing threshold was reduced about 110 dB. The magnetic resonance imaging (MRI) showed the integrity of the 8th

cranial nerve in the inner ear. Accordingly, the patient had a sensorineural hearing loss (SNHL) in both ears. The patient was a candidate for CI in the right ear.

Second patient

Second patient was a 55-year-old woman who had hearing loss for 37 years, and was using hearing aids for 34 years (Fig. 1). She had a complete hearing loss for the past two years. She was speaking loudly and normally, but was unable to answer questions. The patient did not report a history of a similar disease in her first- and second-degree relatives. She experienced a reduction in tactile sensation in the 5th cranial nerve (V2 and V3 dermatomes) on the right side of the face. Under X-ray imaging, increased thickness in skull bone, especially on the right side, and in the right temporal bone was evident. An increase in bone density in the pelvis, thighs, legs and forearms were also observed. Her tympanometry pattern was also flat. The PTA showed a SNHL with at least 110 dB reduction in hearing threshold. MRI showed the 8th cranial nerve integrity in the retrocochlear region.

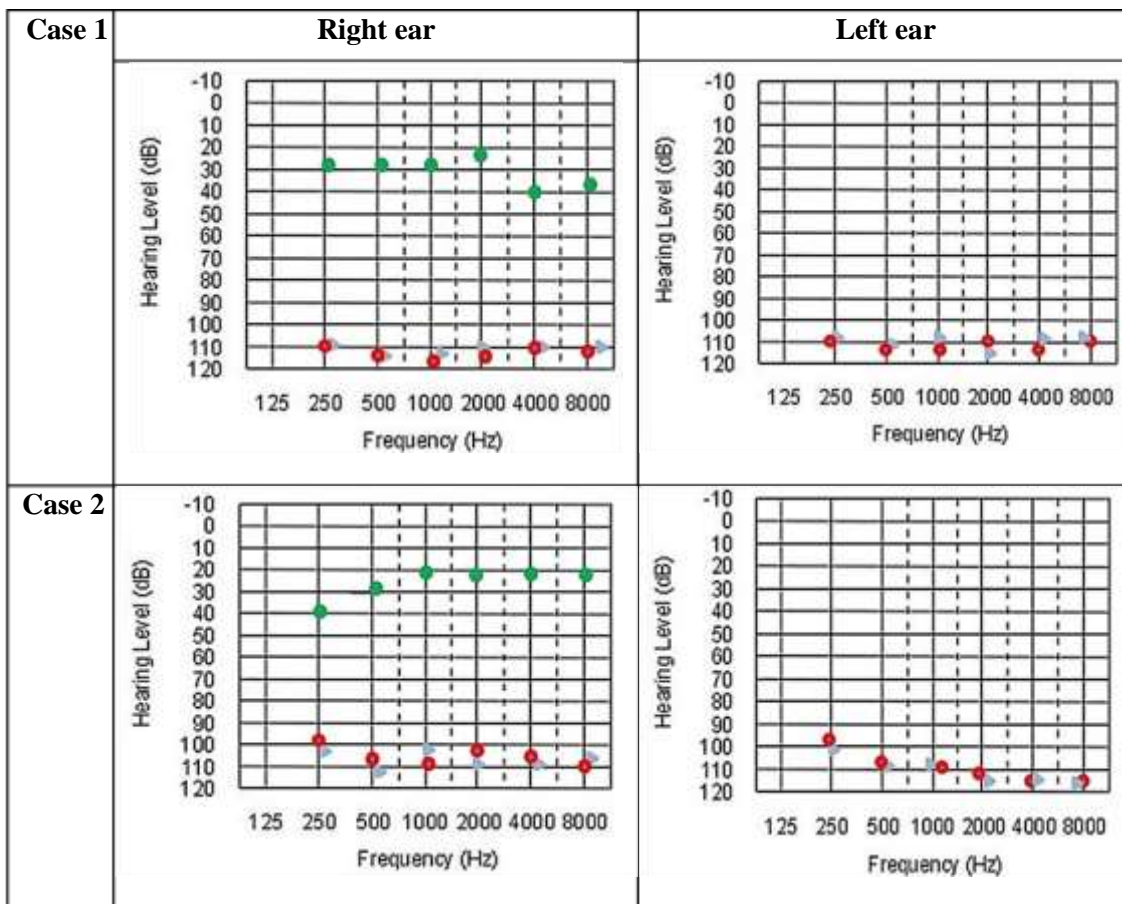


Fig. 2. Pure tone audiometry of two cases. Sensorineural hearing loss, before (red circle) and after (green circle) cochlear implantation. Note that both cochlear implantations are done on the right side.

Cochlear implantation

Both patients underwent CI in Amir A’lam Hospital, Tehran, Iran, in 2017. For the first case, a classic mastoidectomy and posterior tympanotomy was performed. Because of temporal bone involvement in the second case, surgery was not possible by the mentioned methods. Therefore, first a deep groove into the lower part of the external ear canal was created after the tympanomeatal flap elevation. Since the observation of the round window was not possible, a 30° endoscope was used. The electrode was passed through the groove into the middle ear. Therefore, the round window was observed and opened, and the electrode was directed into the apex. The groove was filled with bone dust to avoid the electrode from making contact with

ear canal skin. In addition, the receiver was fixed in the posterior superior aspect of the mastoid.

Results

The electrode impedance test and neural response telemetry (NRT) were performed during operation. They showed appropriate results in both patients. Fig. 2 shows the PTA results before and one month after CI. After treatment, SNHL was compensated alone. In the first and second patients, the auditory threshold improved by 70–80 dB and 60–90 dB, respectively. Patients were satisfied with their hearing three months after the operation, and were able to speak properly. Fig. 3 illustrates the skull CT scan images of the second case before and after CI. Table 1 presents

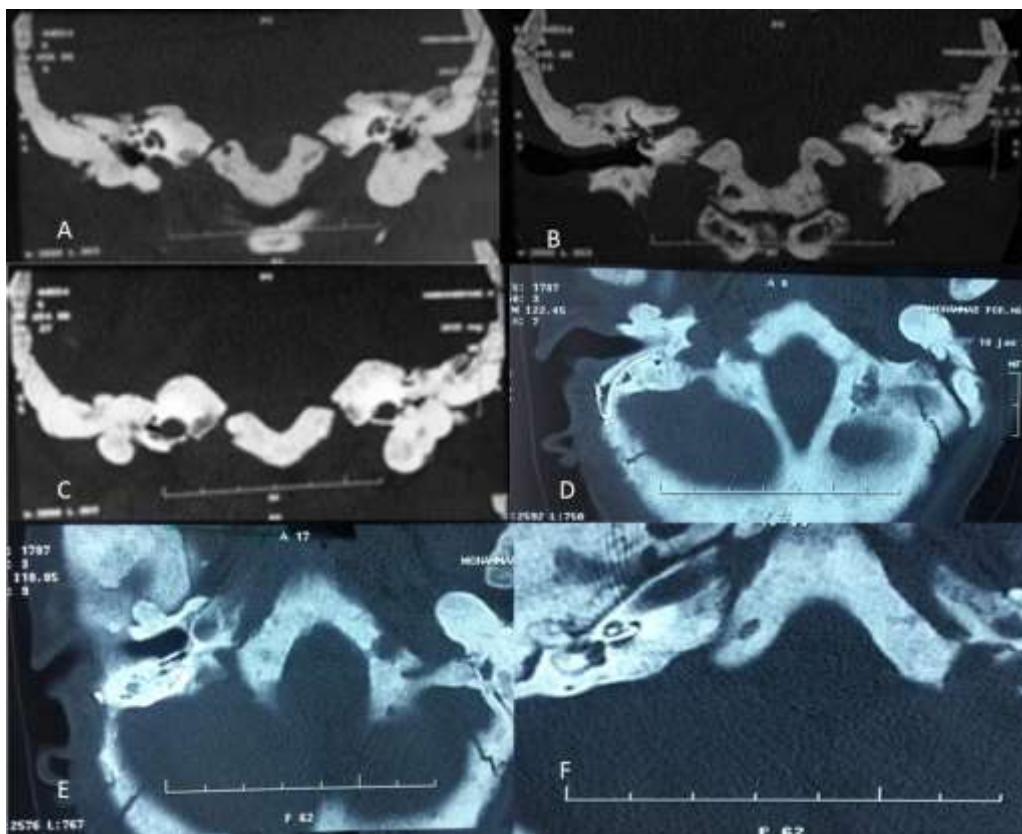


Fig. 3. The sections of skull CT scan images before (A, B, C) and after cochlear implantation (D, E, F).

the impedance test results in the first patient after CI, indicating her good status.

Discussion

The OP is a rare disease whose complications, such as bilateral dysfunction of the inner ear, require CI or auditory brainstem implant (ABI). No definitive treatment has been introduced for OP, and the present treatments are symptomatic and conservative. The OP prognosis is poor in children. If it occurs in adults, their survival is similar to normal population [1]. Increase in temporal bone thickness and decrease in mastoid air cells and in the diameter of internal and external ear canals and Eustachian tube causes a variety of hearing impairments such as tinnitus, conductive hearing loss, SNHL, and mixed hearing loss in OP patients [3]. Evidence on hearing loss occurrence and its progression in patients with OP is diverse, which seems

to be influenced by the hereditary pattern and the patients' age. In a study, infants and children with autosomal recessive OP aged 9 years (mean age = 2.5 years) were monitored for hearing loss. The findings showed that the risk of complete hearing loss in infants was 25% during the first year and 78% during the follow-up period [3]. In one case study, a slower progress was observed in a 37-years-old patient with OP and chronic otitis media. At the age of 40 years, he had severe bilateral tinnitus and then, at the age of 52 years, severe mixed hearing loss occurred with a hearing threshold decline of 40–70 dB [4]. Our study reported two patients with OP suffering from SNHL. They were from different age groups in Iran with a population of more than 80 million. The results showed that CI in these patients was safe and effective, but it may have complications if performed by inexperienced surgeons. In a similar study by Szymanski et al. [2],

Table 1. The electrode impedance result of first case after cochlear implantation

Common ground			Monopolar 1		Monopolar 2		Monopolar 1 and 2									
Electrode	Impedance	Status	Impedance	Status	Impedance	Status	Impedance	Status								
1	16.5	OK	17.2	OK	16.5	OK	15.4	OK								
2	14.9	OK	15.8	OK	15.1	OK	15	OK								
3	15.3	OK	16.2	OK	15.5	OK	15.4	OK								
4	15.1	OK	16	OK	15.3	OK	15.2	OK								
5	12.7	OK	13.7	OK	13	OK	12.9	OK								
6	10.4	OK	11.5	OK	11.1	OK	11	OK								
7	8.3	OK	9.6	OK	8.6	OK	8.9	OK								
8	8.1	OK	9.4	OK	8.8	OK	8.6	OK								
9	6.5	OK	7.9	OK	7.2	OK	7.1	OK								
10	5.9	OK	7.3	OK	6.6	OK	6.5	OK								
11	6.5	OK	8	OK	7.4	OK	7.2	OK								
12	7.2	OK	8.7	OK	8	OK	7.9	OK								
13	5.7	OK	7.2	OK	6.6	OK	6.5	OK								
14	5.1	OK	6.5	OK	5.9	OK	5.8	OK								
15	6.5	OK	8	OK	7.3	OK	7.2	OK								
16	6	OK	8.1	OK	7.5	OK	7.4	OK								
17	6.1	OK	7.6	OK	6.9	OK	6.8	OK								
18	6.5	OK	7.6	OK	7.4	OK	7.3	OK								
19	5.2	OK	6.7	OK	6.1	OK	6	OK								
20	5.4	OK	6.9	OK	6.3	OK	6.2	OK								
21	5.9	OK	7.3	OK	6.6	OK	6.6	OK								
22	6.8	OK	8.4	OK	7.5	OK	7.5	OK								
Electrode	1	2	3	4	5	6	7	8	9	10	11	12	13	14	15	16
Report	5.1	4.5	4.3	4.5	5.3	5.9	6.4	6.4	5.9	6.9	6.4	7.2	6.7	6.4	6.9	6.7

CI was also successful. Their case was a 52-year-old woman who had hearing loss at the right ear due to OP. At the age of 38, the patient also suffered from SNHL in the left ear, and had sudden deafness in the right ear four months before CI. PTA showed a decrease of about 90 dB in

hearing threshold. The patient’s speech perception was about 10%. Tympanogram was normal with no stapedius reflex. Based on the X-ray imaging, the temporal bone was dense and most of mastoid air cells were occluded. The patient received bilateral CI using standard posterior

tympanotomy. Their findings showed that CI had stable and appropriate results during three years of evaluation. After six months, speech improved by 75%, and hearing threshold was 30 dB according to the PTA. After two years, CT scan showed a radiolucent line around the implant.

Since the results of ABI are unpredictable even in the present time, it is better to perform CI rather than ABI, if possible [5,6]. Taking some measures before and during CI can improve clinical outcomes in these patients [7]. The internal auditory canal and the compression amount of the 8th cranial nerve should be evaluated before surgery based on auditory brainstem response, and promontory stimulation should be used to ensure its function. Since the involvement of the petrous part of the temporal bone in OP patients varies from mild to very severe and may make it challenging to perform CI, the surgeon should be able to make changes in surgery techniques. In the first patient, the mastoid was well aerated; therefore, we were able to perform classic mastoidectomy and posterior tympanotomy. However, in the second patient, there was a severe temporal bone change and a considerable narrowing of the external ear canal, which led to using endoscopic surgery with modified technique through a deep groove cut in the external ear canal. An experienced surgeon who is familiar with all CI techniques, should be able to make technical changes in the operation. The use of endoscope in CI surgery can be effective, as it was reported in the second patient that electrode insertion was possible with only endoscopic vision. In patients with advanced temporal bone involvement, it is practically impossible and time-consuming to find the facial nerve; therefore, the use of facial nerve monitoring is important to prevent nerve damage [8,9]. Head and neck manipulation should be avoided during CI surgery. Although the bone looked very dense, it was strong and the patient was susceptible to bone fracture and its complications, especially in the neck [9,10].

Conclusion

Cochlear implantation in patients with OP is safe

and successful. Based on their anatomical changes in the temporal bone, the surgical technique may need to be altered for each patient. Hence, the surgeon should be flexible and ready to change the approach during surgery.

Acknowledgments

We would like to thank our patients for their contribution to this study.

Conflict of interest

The authors state that there was no conflict of interest.

References

1. Stark Z, Savarirayan R. Osteopetrosis. *Orphanet J Rare Dis.* 2009;4:5. doi: <https://doi.org/10.1186/1750-1172-4-5>
2. Szymanski M, Zasławska K, Trojanowska A, Szymanska A, Zadrozniak M. Osteopetrosis of the temporal bone treated with cochlear implant. *J Int Adv Otol.* 2015; 11(2):173-5. doi: [10.5152/iao.2015.449](https://doi.org/10.5152/iao.2015.449)
3. Dozier TS, Duncan IM, Klein AJ, Lambert PR, Key LL Jr. Otologic manifestations of malignant osteopetrosis. *Otol Neurotol.* 2005;26(4):762-6. doi: [10.1097/01.mao.0000178139.27472.8d](https://doi.org/10.1097/01.mao.0000178139.27472.8d)
4. Gniady JP, Ronis ML. Progressive mixed type hearing loss in an adult male with osteopetrosis. *Laryngoscope.* 2009;119(S1):S39-S39. doi: [10.1002/lary.20364](https://doi.org/10.1002/lary.20364)
5. Sennaroglu L, Ziyal I. Auditory brainstem implantation. *Auris Nasus Larynx.* 2012;39(5):439-50. doi: [10.1016/j.anl.2011.10.013](https://doi.org/10.1016/j.anl.2011.10.013)
6. Verhulst S, Jagadeesh A, Mauermann M, Ernst F. Individual differences in auditory brainstem response wave characteristics: relations to different aspects of peripheral hearing loss. *Trends Hear.* 2016;20:1-20. doi: [10.1177/2331216516672186](https://doi.org/10.1177/2331216516672186)
7. Motasaddi Zarandy M, Saki S, Saki N. The first step toward improving cochlear implant insertion using a new technique called slide method (Motasaddi Method). *Int J Pharm Res Allied Sci.* 2016;5(2):110-3.
8. Hsieh HS, Wu CM, Zhuo MY, Yang CH, Chao H, Hwang CF. Intraoperative facial nerve monitoring during cochlear implant surgery. an observational study. *Medicine (Baltimore).* 2015;94(4):e456. doi: [10.1097/MD.0000000000000456](https://doi.org/10.1097/MD.0000000000000456)
9. Rathod AK, Dhake RP, Borde MD. Traumatic multiple cervical spine injuries in a patient with osteopetrosis and its management. *Eur Spine J.* 2017;26:229-35. doi: [10.1007/s00586-017-5083-x](https://doi.org/10.1007/s00586-017-5083-x)
10. Aslan A, Baykal YB, Uysal E, Atay T, Kirdemir V, Baydar ML, et al. Surgical treatment of osteopetrosis-related femoral fractures: two case reports and literature review. *Case Rep Orthop.* 2014;2014:891963. doi: [10.1155/2014/891963](https://doi.org/10.1155/2014/891963)