

Successful Angioembolization of a Stable Grade 4 Liver Injury

Shogeta Ramanathan^{1,2}, Ikhwan Sani Mohamad^{1,2}, Mohammad Zawawi Ya'acob^{1,2}, Rosnelifaizur Ramely^{1,2}, Zhan Huai Teoh^{1,2}, Chandran Nadarajan^{2,3}

¹ Department of Surgery, Hospital Universiti Sains Malaysia, Kubang, Kerian, Kelantan, Malaysia

² Hospital Universiti Sains Malaysia, Kubang Kerian, Kelantan, Malaysia

³ Department of Radiology, Hospital Universiti Sains Malaysia, Kubang, Kerian, Kelantan, Malaysia

Received: 07 Sep. 2021; Accepted: 18 Mar. 2022

Abstract- Traumatic liver injury can be classified by grading using American Association with Surgery Trauma (AAST). We presented a case of a 22-year-old female who had a motor vehicle accident and sustained a stable Grade 4 liver injury. An angioembolization was performed by the interventional radiologist team, which successfully occluded all the extravasation of the bleed. If the patient is hemodynamically stable in high grade or bleeding liver injury, a non-invasive technique such as angioembolization could be practiced at the bleeding site to minimize or stop the bleeding.

© 2022 Tehran University of Medical Sciences. All rights reserved.

Acta Med Iran 2022;60(4):256-258.

Keywords: Trauma; Liver injury; Embolization

Introduction

Intrabdominal injury post-trauma is very crucial and could be life-threatening if not identified and treated. Liver injury is one of the most common among intrabdominal traumatic injuries. In trauma, liver injury is classified by CT scan by American Association with Surgery Trauma (AAST) from grade I till IV (1). The classification includes injuries such as hematoma, lacerations, bleeding, and avulsing injuries to the liver (2). The higher the grade of injury to the liver, the more risk of bleeding and deterioration of the patient's condition. Therefore, they need to be closely monitored and treated. There are pieces of evidence of cases where bleeding liver injuries are commonly managed by a surgical intervention such as liver packing and resection. However, non-invasive procedures such as angioembolization by an interventional radiologist could also be practiced, which have proven the benefits for patients (3).

Case Report

A 22-year-old female had a motor vehicle accident. The patient fell on her right side. Post trauma, patient had

right-sided abdominal pain. The vital signs were stable. Generally, she looked pale. Examination of abdomen noted tenderness on right hypochondrium. Per rectal examination was normal. A Focused assessment sonography for trauma (FAST) scan was done and showed presence free fluid at Morrison's pouch and pouch of Douglas. Blood investigation taken showed the hemoglobin dropped from 8.8 g/dl to 6.1 g/dl. Blood transfusion was given.

A contrast-enhanced computed tomography (CECT) scan of the abdomen performed showed grade 4 liver injury with multifocal active arterial bleed from the hepatic artery at segment IV liver (Figure 1). Patient was hemodynamically stable. On second day of admission, an angio-embolization was done by interventional radiologist team which successfully occlude all the extravasation of bleed (Figure 2).

Post embolization, CECT liver four phase was done and showed resolved multifocal arterial bleed within subcapsular liver hematoma (Figure 3). Patient remained hemodynamically stable. She was transfused with total four-unit packed cell blood transfusion throughout admission. The repeated hemoglobin was 9.9 g/dl. Liver function tests was normal. Patient was closely monitored in ward for one-week post embolization. Clinically

Corresponding Author: I.S. Mohamad

Department of Surgery, Hospital Universiti Sains Malaysia, Kubang, Kerian, Kelantan, Malaysia
Tel: +017 9278535, Fax: +98 2142910703, E-mail address: ikhwansani@yahoo.com.my

Copyright © 2022 Tehran University of Medical Sciences. Published by Tehran University of Medical Sciences

This work is licensed under a Creative Commons Attribution-NonCommercial 4.0 International license (<https://creativecommons.org/licenses/by-nc/4.0/>). Non-commercial uses of the work are permitted, provided the original work is properly cited

patient was improving and was discharged home well.

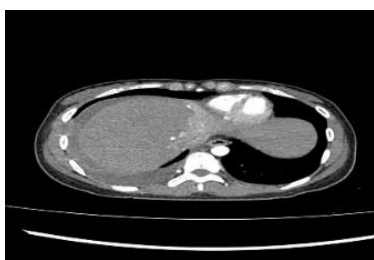


Figure 1. Axial CT Scan showed blushing of contrast at segment 4 liver injury

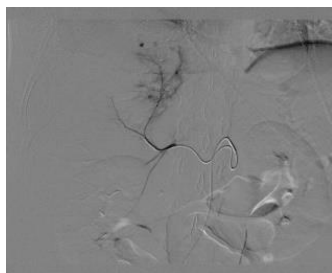


Figure 2. Angiogram showed contrast blushed from the branch of right hepatic artery

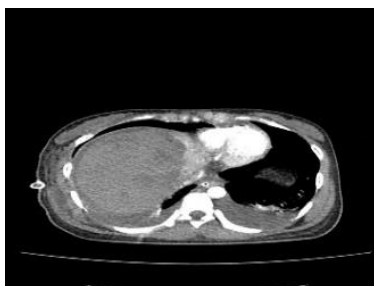


Figure 3. Post angioembolization CT scan showed stable liver injury without evidence of contrast extravasation

Discussion

There were few evidences of non-invasive approach for bleeding liver injuries by performing angio-embolization which showed success in halting the bleed as well as improve patient hemodynamic status and well-being. An angioembolization on high grade liver injury with extravasation of bleeding by CT angiography with hemodynamically stable patient showed successful outcome (4).

Patient can develop complications from high grade liver injury post embolization such as hepatic necrosis which can have persistent liver function test derangement. In this case patient need for hepatic resection. Therefore, close monitoring of patient and watching out for symptoms as abdominal pain, reduced oral intake and signs of bile leak is essential (5).

It also has been evidenced that angioembolization also play a role if unable to halt the bleeding from surgical intervention. Angiography could detect the site of bleeder and can be treated by angioembolization at same setting (6).

Liver injuries are treated either surgical or non-operative approach by the CT abdomen grading system for liver injuries and hemodynamic status of the patient. The procedure of angioembolization of the liver bleeding site involves introducing a vascular catheter through a retrograde common femoral approach, reaching the coeliac trunk, and releasing embolizing agent as gel foam or onyx to the distal hepatic artery at the bleeding spot at the targeted area of the liver. This agent blocks the bleeding site. Sometimes micro coils are used in proximal bleeding sites to stop the bleeding (7).

In our case study, the interventional radiologist used gel foam to the distal hepatic artery bleeding site at segment 4, which successfully occluded the bleeding areas as evidenced with repeated CT liver 4 phase.

It is essential to have a discussion with an interventional radiologist regarding the feasibility for the patient after assessment of the stability of the hemodynamic status. Moreover, it is evidenced to be beneficial in the hemodynamic stable for bleeding liver injuries.

High-grade unstable bleeding liver injuries are commonly treated by surgical intervention. However, with the advancement of technology, angioembolization could be considered as an option of treatment, especially in the hemodynamically stable patient. There is always a risk of complication after surgical intervention on the abdomen. A non-invasive method is always preferred if the patient is fit for the procedure.

References

1. Tinkoff G, Esposito TJ, Reed J, Kilgo P, Fildes J, Pasquale M, et al. American Association for the Surgery of Trauma Organ Injury Scale I: spleen, liver, and kidney, validation based on the National Trauma Data Bank. *J Am Coll Surg* 2008;207:646-55.
2. Yoon W, Jeong YY, Kim JK, Seo JJ, Lim HS, Shin SS, et al. CT in blunt liver trauma. *Radiographics* 2005;25:87-104.
3. Salsamendi JA, Quintana DA, Kably IS, Narayanan G. Special Considerations for Embolization in Trauma Cases. *Endovascular Today* 2013:42-50.
4. Porter DJ, Walter A, Makin I, Gunn E. Non-Operative Management of A Grade 4 Liver laceration. *WJPMR* 2019;5:217-20.

Successful angioembolization of a stable grade 4 liver injury

5. Abdelrahman H, Ajaj A, Atique S, El-Menyar A, Al-Thani H. Conservative management of major liver necrosis after angioembolization in a patient with blunt trauma. *Case Rep Surg* 2013;2013:954050.
6. John F, Varkey MR. Selective Arterial Embolization in Hepatic Trauma. *Int J Case Rep Images (IJCRI)*. 2014;1;5:712-6.
7. Wallis A, Kelly MD, Jones L. Angiography and embolisation for solid abdominal organ injury in adults-a current perspective. *World J Emerg Surg* 2010;5:18.