

Anti-Inflammatory and Antioxidative Effects of Sumatriptan Against Doxorubicin-Induced Cardiotoxicity in Rat

Mohammad Sheibani¹, Hedyeh Faghir-Ghanesefat^{2,3}, Yaser Azizi^{4,5}, Tahmineh Mokhtari^{6,7}, Hasan Yousefi-Manesh^{2,3}, Roya Sattarzadeh Badkoubeh⁸, Amir Hossein Emami⁹, Ahmad Reza Dehpour^{2,3}

¹ Department of Pharmacology, School of Medicine, Iran University of Medical Sciences, Tehran, Iran

² Experimental Medicine Research Center, Tehran University of Medical Sciences, Tehran, Iran

³ Department of Pharmacology, School of Medicine, Tehran University of Medical Sciences, Tehran, Iran

⁴ Physiology Research Center, School of Medicine, Iran University of Medical Sciences, Tehran, Iran

⁵ Department of Physiology, School of Medicine, Iran University of Medical Sciences, Tehran, Iran

⁶ CAS Key Laboratory of Mental Health, Institute of Psychology, Beijing, China

⁷ Department of Psychology, University of Chinese Academy of Sciences, Beijing, China

⁸ Cardiology Department of Imam Khomeini Hospital, Tehran University of Medical Sciences, Tehran, Iran

⁹ Department of Hematology-Oncology, Imam Khomeini Hospital Complex, Tehran University of Medical Sciences, Tehran, Iran

Received: 06 Jan. 2021; Accepted: 21 Jun. 2021

Abstract- The clinical use of doxorubicin as a potent chemotherapeutic agent is limited due to its dose-dependent cardiotoxicity. Oxidative stress and inflammatory pathways have a pivotal role in doxorubicin-induced cardiotoxicity. Sumatriptan, a 5-hydroxytryptamine (5-HT)_{1B/1D} agonist that is mainly used to relieve migraine pain, has suggested exerting protective effects in numerous pathological conditions through antiinflammatory properties. The aim of the present study was to investigate the effects of sumatriptan on doxorubicin-induced cardiotoxicity and the contribution of anti-inflammation and antioxidative responses. Cardiotoxicity was induced by the administration of doxorubicin three times a week (2.5 mg/kg i.p) for two consecutive weeks on male rats. The animals were divided into four groups, including Control, Sumatriptan (0.1 mg/kg) received group, doxorubicin received group, and Doxorubicin+Sumatriptan (0.1 mg/kg) received group. Sumatriptan was administered 30 min before every injection of doxorubicin. On the last day of the second week, the body weight, mortality rate, electrocardiogram (ECG) and histopathological changes, cardiac inotropic study, and biochemical factors were evaluated. The loss of body weight, mortality rate, ECG parameters, reduction of papillary muscle contractility force as well as histopathological scores following administration of doxorubicin indicated severe cardiac damage. However, treatment with sumatriptan inhibited the functional and structural impairment induced by doxorubicin. In addition, sumatriptan could significantly reduce cardiac tissue levels of malondialdehyde (MDA) and tumor necrosis factor-alpha (TNF- α), which were increased in the doxorubicin-treated rats. This study illustrated the protective effects of sumatriptan on decreasing doxorubicin-induced cardiac toxicity and mortality rate in part through inhibition of inflammatory and oxidative stress pathways.

© 2021 Tehran University of Medical Sciences. All rights reserved.

Acta Med Iran 2021;59(7):406-415.

Keywords: Doxorubicin; Sumatriptan; Cardiotoxicity; Oxidative stress; Inflammation

Introduction

Doxorubicin (DOX), as the anthracycline antibiotic, is widely used as an effective antibiotic and anticancer

agent in the treatment of a wide range of malignancies (1). However, the clinical application of doxorubicin is limited due to its adverse pathological effects, especially treatment-related cardiotoxicity (2). The cardiac adverse

Corresponding Author: A.R. Dehpour

Department of Pharmacology, School of Medicine, Tehran University of Medical Sciences, Tehran, Iran

Tel: +98 2188973652, Fax: +98 2166402569, E-mail addresses: dehpoura@sina.tums.ac.ir; dehpour@yahoo.com

Copyright © 2021 Tehran University of Medical Sciences. Published by Tehran University of Medical Sciences

This work is licensed under a Creative Commons Attribution-NonCommercial 4.0 International license (<https://creativecommons.org/licenses/by-nc/4.0/>). Non-commercial uses of the work are permitted, provided the original work is properly cited

effects of DOX during a chemotherapy regimen can be acute, chronic, or even gradually persistent after the termination of DOX therapy (3). It has been suggested that doxorubicin-induced cardiac functional and structural impairment occur through various molecular pathways, including the formation of free radical, oxidative stress activation, cell membrane damage, disruption of transmembrane ion channels, mitochondrial damage, activation of endothelial nitric oxide synthase (eNOS), and release of inflammatory cytokines (4,5). Several strategies have been suggested for cardiotoxic effects of doxorubicin (6,7). In several animal and clinical researches, antiinflammatory or antioxidative agent are used to reduce DOX-induced cardiotoxicity. Various studies wanted to explain the underlying cellular mechanism of this medication's undesirable effects. Because of the multifactorial nature of DOX cardiac effects, the precise pathophysiology underlying DOX-induced cardiotoxicity is not fully understood (8,9).

Recent studies have claimed that there is an association between some adverse effects of doxorubicin and the level of serotonin with involvement of 5-HT receptors (10,11).

Serotonin (5-HT) is a bioactive amine produced mainly by enterochromaffin cells, and stored in platelets; it has a wide range of physiological functions through impact on its receptors. Serotonin has been involved in regulation of normal cardiac development and homeostasis (12,13). Sumatriptan, a 5-hydroxytryptamine 1B/D receptors (5-HT_{1B/D}) agonist, is involved in pain and used to treat migraine and cluster headaches (14). Both 5-HT_{1B} and 5-HT_{1D} receptors are pre-synaptic auto-receptors and anti-migraine effect of this drug exerts via inhibition of the release of serotonin neurotransmitters (15,16). It has been proposed that the anti-migraine properties of sumatriptan are mainly due to vasoconstriction of dilated meningeal vessels (16). However, there are evidences that low doses of sumatriptan have protective effects in inflammatory conditions not related to its anti-migraine properties. These effects may be attributed to modulation of inflammatory pathway through suppression of inflammatory cytokines and proteins (17,18). Moreover, previous studies have confirmed further effects of sumatriptan, such as its antioxidative and antiinflammatory properties (19,20). Some studies have suggested that lower doses of sumatriptan may have protective effects on experimental models of inflammation such as cardiac injury and neuropathy through modulating inflammatory responses. Part of the protective effects of sumatriptan was mediated by

reduction of tumor necrosis factor- α (TNF- α) cytokine production and suppression of some oxidative factors such as Malondialdehyde (MDA) (18,21). According to the antiinflammatory and antioxidative properties of sumatriptan and also the critical role of inflammation and oxidative stress in the pathophysiology of DOX-induced cardiotoxicity, we aimed to investigate the potential therapeutic effects of lower doses of sumatriptan in DOX-induced cardiotoxicity in the rat model.

Materials and Methods

Animals and study protocol

The experiment was performed on male Sprague-Dawley rats weighing 250-300 g. Animals were housed under controlled laboratory conditions with a 12 h light/dark in standard polycarbonate cages that included controlled ambient temperature ($23\pm 1^\circ$ C), and free access to standard animal chow and water. Animals were monitored daily three times a day to monitor behavior and health. All experimental procedures were under the guidelines of the National Institute of Health Guide for the Care and Use of Laboratory Animals (NIH publication no. 85-23, revised 1985). The Ethical Committee of Tehran University of Medical Sciences approved all of in vivo work (Ethical number: IR.TUMS.MEDICINE.REC.1398.364). The animal study period was two weeks for each group. Because doxorubicin injection was performed for 14 days. Animals were randomly assigned to four groups, and each group consisted of 12 rats. Group 1: Control group that received normal saline, Group 2: Doxorubicin-treated group that received 2.5 mg/kg, i.p (5) of doxorubicin HCl (DOX) three times per week for 14 days, Group 3: Sumatriptan-treated group that only received sumatriptan (0.1 mg/kg, i.p.) (22) without administration of doxorubicin three times per week for 14 days, and Group 4: Doxorubicin+Sumatriptan (0.1 mg/kg, i.p.)- treated group that received sumatriptan 30 minutes before every injection of doxorubicin. To perform all interventions such as surgical procedure and ECG using the subcutaneous needle was used to complete anesthesia to minimize an animal's suffering.

In a pilot study, four different doses of sumatriptan (0.1, 0.3, 1, and 3 mg/kg) were used to determine the most effective dose of sumatriptan. No significant protective effect was found after analysis of the results from the dose of 0.3 mg/kg. Also, non-protective and even destructive effects were observed at the higher doses of sumatriptan (1 and 3 mg/kg). The most effective and protective response achieved from the sumatriptan at the dose of 0.1

Sumatriptan protects against doxorubicin-induced cardiotoxicity

mg/kg. Because of this reason, we selected this dose for our study.

Drugs (DOX administered in the DOX-received groups and normal saline administered in the control group) were injected three times a week for two weeks. Sumatriptan was injected 30 min before every injection of DOX and normal saline. The total cumulative treatment of DOX administered to each rat was equal to 15 mg/kg (i.p.). All drugs were purchased from Sigma-Aldrich Company (St. Louis, MO, USA). The study protocol was performed under the literature (5).

Survival study and body weight

Animals were kept in standard cages so that each cage consisted of 3 rats. The mortality rate was observed and recorded daily. Body weights were measured twice per week during the experiment.

Electrocardiography (ECG)

Electrocardiogram (ECG) was recorded on the first day of injection and after the last dose of doxorubicin. After applying the anesthesia using diazepam (5 mg/kg, i.p.) and ketamine (50 mg/kg, i.p.) (23,24), needle electrodes were inserted subcutaneously into the limb to continuously monitor the lead II electrocardiogram using the PowerLab data acquisition system (Chart 5.5, AD Instruments, and PowerLab). Doxorubicin-induced cardiotoxicity was determined by assessing the QRS complex, QT and RR interval, and PR segment.

Evaluation of the left ventricular papillary muscle contraction

At the end of the experiment, and after induction of anesthesia, the heart was removed and the left ventricular papillary muscle was isolated in physiologic salt buffer solution (containing NaCl: 112 mM, MgCl₂: 1mM, KCl: 5 mM, NaH₂PO₄: 0.5 mM, NaHCO₃: 25 mM, Glucose: 10 mM, CaCl₂: 1.8 mM (pH: 7.4), KH₂PO₄: 0.5 mM, and EDTA: 0.004 mM) with 5% CO₂ and 90% O₂ at a temperature of 33° C. Then, the papillary muscle was attached to an isometric force transducer under a tension of 500 mg in a 25 ml glass chamber in an organ bath and then was equilibrated for 90 min (ADI Instrument, PowerLab, Spain). The threshold was determined by exposing the muscle to electrical field stimulation at a frequency of 1 Hz, followed by presenting it at a frequency of 20% higher than the limit for the contractile force (5,25).

Measurement of tissue levels of MDA, SOD, and TNF- α

Tissue samples were kept at -80° C for further analysis. To determine concentrations of Malondialdehyde (MDA), Superoxide dismutase (SOD), and Tumor necrosis factor-alpha (TNF- α) in the tissue samples; heart tissue of the animals was homogenized in a solution containing 3.75 ml of the phosphate-EDTA buffer and 1 ml of 25% HPO₃. After centrifugation at 100,000 g at 4° C for 10 min, 0.5 ml of supernatant was obtained and was mixed with 4.5 ml of phosphate-EDTA buffer (pH=8.0). Then, the samples were incubated at room temperature for 15 min. ELISA reader determined concentrations of MDA, SOD, and TNF- α in the tissue samples at wavelength ranges of (405-414) and (440-460 μ m), respectively (26).

Histopathological assessment

On the last day of the experiment, after the last dose of doxorubicin administration, animals were anesthetized by diazepam (5 mg/kg, i.p.) and ketamine (50 mg/kg, i.p.), and their hearts were harvested for further studies including biochemical and histological assessment. Animals' death was confirmed after completely harvesting their hearts. After excision of the animal's heart, the samples were fixed in formalin 10% and weighed. The left ventricle was embedded in paraffin, and 5 μ m thickness tissue sample was then stained with hematoxylin and eosin (H & E). Histopathological changes, including damages to cardiomyocytes, myofibril loss, and cytoplasmic vacuolization, were semi-quantitatively scored on a scale of 0-3 under a light microscope (\times 200; Olympus-2B). The sections were reviewed by the expert pathologist, who was blind to group assignment.

Statistical analysis

GraphPad Prism (version 6) software was used for statistical analysis. One-way ANOVA was performed, followed by Tukey's posthoc test (multi-group comparison). For all experiments, the results were expressed as mean \pm Standard Error of the Mean (S.E.M). Differences with a *P* less than 0.05 were considered statistically significant.

Results

The effect of sumatriptan on body weight and mortality

During two weeks of the experiment, the bodyweight of animals increased in control and sumatriptan-treated groups. Whereas it was found that the administration of

DOX (15 mg/kg, i.p) caused significant weight loss ($P<0.05$, Table 1). Administration of doxorubicin, along with sumatriptan (0.1 mg/kg), could significantly

increase the bodyweight in comparison with the DOX group ($P<0.05$).

Table 1. The effect of sumatriptan on body weight in DOX-induced cardiotoxicity in rats.

Groups Days	Control	DOX	Sumatriptan (0.1 mg/kg)	DOX+Sumatriptan (0.1 mg/kg)
Day 1	251.63±3.17	245.22±3.67	247.44±2.41	248.26±2.48
Day 4	255.55±2.69	243.49±3.46	250.87±2.27	245.58±3.39
Day 7	257.41±2.75	234.93±2.94 *	252.55±3.54 #	243.74±3.76 *,#
Day14	259.24±3.32	230.66±4.53 *	255.49±2.89 #	242.73±3.24 *,#

* $P<0.05$ compared to the control group, # $P<0.05$ compared to the DOX group (n=12). Data are presented as Mean ± S.E.M. DOX: doxorubicin

In addition, there was no mortality in the control, sumatriptan (0.1 mg/kg), and DOX+sumatriptan (0.1 mg/kg) groups. While the mortality rate in the DOX group was remarkable (6 out of 12 rats) at the end of the experiment (Figure 1). The survival rate significantly increased in the DOX+sumatriptan (0.1 mg/kg) group

(n=12) compared with doxorubicin-treated animals (100 versus 50%, $P<0.001$). Our close observation during the period of the study revealed the signs of congestive heart failure, including extensive fluid retention in animals' pleural cavities, which was then confirmed with histopathological and cardiac ionotropic analysis.

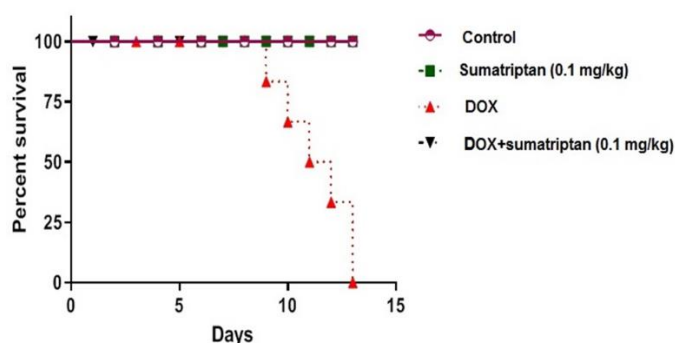


Figure 1. The effect of sumatriptan on DOX-induced mortality in rats. There was no mortality in the control group, sumatriptan (0.1 mg/kg) treated group, and DOX+sumatriptan (0.1 mg/kg) treated group. The survival rate significantly increased in the DOX+sumatriptan (0.1 mg/kg) treated group (n=12) compared with doxorubicin-treated animals (100 versus 50%, $P<0.001$). DOX: doxorubicin

The Effect of sumatriptan on the papillary muscle excitation and contraction

According to the results, there were statistical differences in the left ventricular papillary muscle excitation threshold between the DOX and DOX+sumatriptan (0.1 mg/kg) groups with the control group ($P<0.001$, Figure 2a). The excitation threshold of papillary muscles significantly decreased in the sumatriptan (0.1 mg/kg) treated group compared with the DOX group ($P<0.001$, Figure 2a). Also, administration of sumatriptan (0.1 mg/kg) 30 min before DOX treatment remarkably improved the papillary muscle excitation

threshold ($P<0.001$, Figure 2a).

Papillary muscle contraction study presented significant differences between the DOX and DOX+sumatriptan (0.1 mg/kg) groups with the control group ($P<0.001$). Based on Figure 2b, there was a significant reduction in the papillary muscle contraction following DOX administration compared to the sumatriptan (0.1 mg/kg) treated group ($P<0.001$). However, the papillary muscle contraction force increased in the DOX+sumatriptan (0.1 mg/kg) treated group compared to the DOX group ($P<0.01$)

Sumatriptan protects against doxorubicin-induced cardiotoxicity

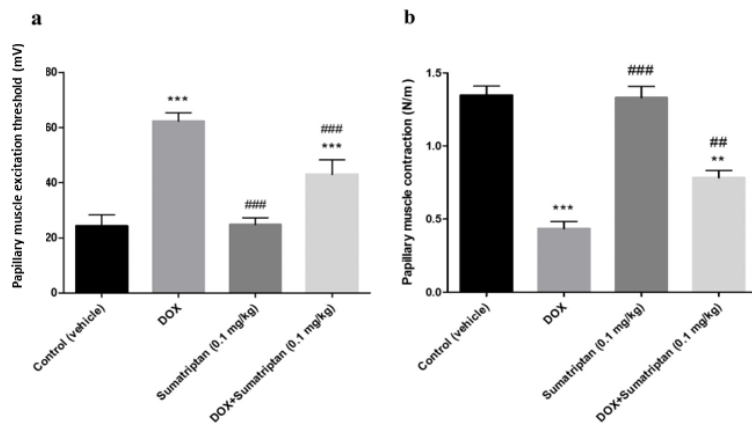


Figure 2. The effect of sumatriptan on papillary muscle excitation threshold and contraction in DOX-induced cardiotoxicity in rats. (a) Papillary muscle excitation threshold (mV), (b) papillary muscle contraction (N/m²). ** $P < 0.01$ and *** $P < 0.001$ compared to the control group, ## $P < 0.01$ and ### $P < 0.001$ compared to the DOX group (n=12). Data are presented as Mean±S.E.M. DOX, doxorubicin

The protective effect of sumatriptan on ECG parameters changes

Based on Figure 3, administration of doxorubicin increased the duration of QRS complex, QT interval, PR interval, and RR segment compared to the control group ($P < 0.001$, $P < 0.001$, $P < 0.05$, and $P < 0.001$, respectively). Also, there was a significant elevation in QT and RR

intervals between the DOX+sumatriptan (0.1 mg/kg) treated group and the control group ($P < 0.001$). Whereas, co-administration of DOX and sumatriptan (0.1 mg/kg) remarkably improved DOX-induced changes in all ECG parameters (QRS and QT interval: $P < 0.01$, PR and RR interval: $P < 0.05$) in comparison with the DOX group.

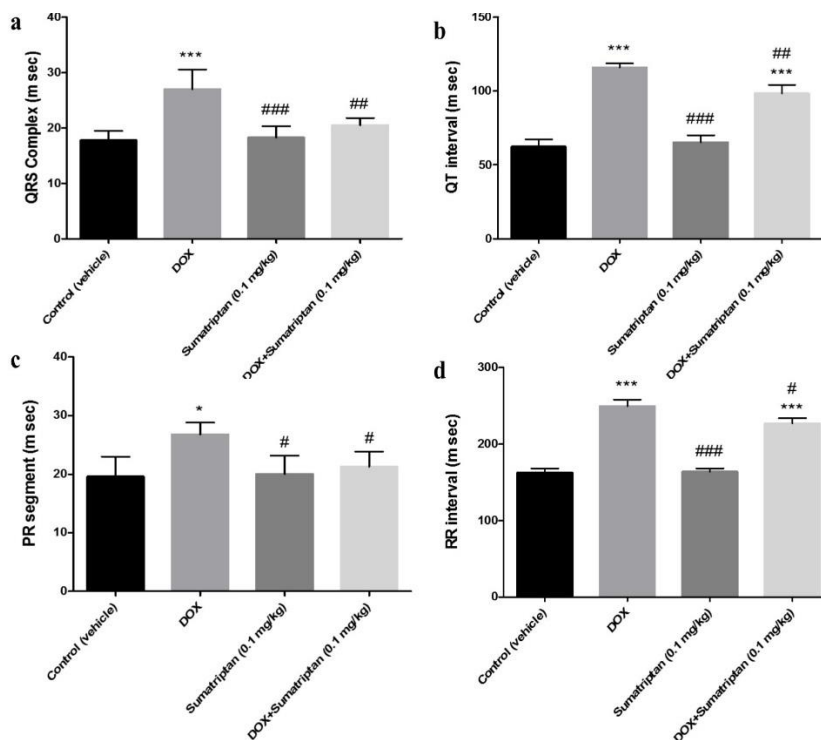


Figure 3. The effect of sumatriptan on ECG alterations in DOX-induced cardiotoxicity in rats. * $P < 0.05$ and *** $P < 0.001$ compared to the control group, # $P < 0.01$, ## $P < 0.01$, and ### $P < 0.001$ compared to the DOX group (n=12). Data are presented as Mean±S.E.M. DOX, doxorubicin

Effects of sumatriptan on tissue levels of SOD, MDA, and TNF- α

Statistical analysis of the tissue levels of SOD and MDA, as indicators of oxidative stress, did not show any significant difference between the control group and the sumatriptan (0.1 mg/kg) treated group. Based on Table 2, there was a considerable decrease in the tissue levels of SOD in the DOX and the DOX+sumatriptan (0.1 mg/kg) treated group compared with the control group ($P<0.01$ and $P<0.05$, respectively). However, a remarkable increase in SOD concentration was shown in the DOX+sumatriptan (0.1 mg/kg) treated group compared to the DOX group ($P<0.05$).

Evaluation of the tissue MDA level demonstrated the statistical difference between the DOX and the

DOX+sumatriptan (0.1 mg/kg) treated group compared with the control group ($P<0.001$). Also, there was a significant decrease in the concentration of MDA in the sumatriptan (0.1 mg/kg) and DOX+sumatriptan (0.1 mg/kg) treated groups compared to the DOX group ($P<0.001$ and $P<0.05$, respectively).

Statistical analysis of the tissue level of TNF- α , as an inflammatory cytokine, showed a significant increase following the administration of DOX compared to the control group ($P<0.001$, Table 2). Also, a significant difference was found between the sumatriptan (0.1 mg/kg) treated group and the DOX group ($P<0.001$). However, the tissue level of TNF- α was considerably lower in the DOX+sumatriptan (0.1 mg/kg) treated group compared to the DOX group ($P<0.01$, Table 2).

Table 2. The effect of sumatriptan on tissue levels of SOD, MDA, and TNF- α in DOX-induced cardiotoxicity in rats

Groups	Control	DOX	Sumatriptan (0.1 mg/kg)	DOX + Sumatriptan (0.1 mg/kg)
Markers				
SOD (U/mg)	38.95 \pm 2.25	27.51 \pm 2.13**	35.33 \pm 2.21 ##	31.46 \pm 2.49 *,#
MDA (μg/mg)	31.45 \pm 4.29	183.62 \pm 5.19 ***	29.18 \pm 3.15 ###	137.52 \pm 4.34 ***, #
TNF-α (pg/mg)	3.11 \pm 2.13	7.65 \pm 0.75 ***	2.93 \pm 0.21 ###	5.48 \pm 0.56 **, ##

* $P<0.05$, ** $P<0.01$, and *** $P<0.001$ compared to the control group, # $P<0.05$, ## $P<0.01$, and ### $P<0.001$ compared to the DOX group (n=12). Data are presented as Mean \pm S.E.M. DOX: doxorubicin

Histopathological examination

Figure 4 shows a microscopic evaluation of the rat's myocardium. There were no significant histological changes in the sumatriptan (0.1 mg/kg) treated group compared to the control group. There were considerable morphological changes such as mononuclear cell

infiltration, myofibrillar loss, cytoplasmic vacuolization, and tissue disarrangement in the doxorubicin-received rats.

However, co-administration of DOX and sumatriptan (0.1 mg/kg) decreased the severity of cardiac tissue damages significantly.

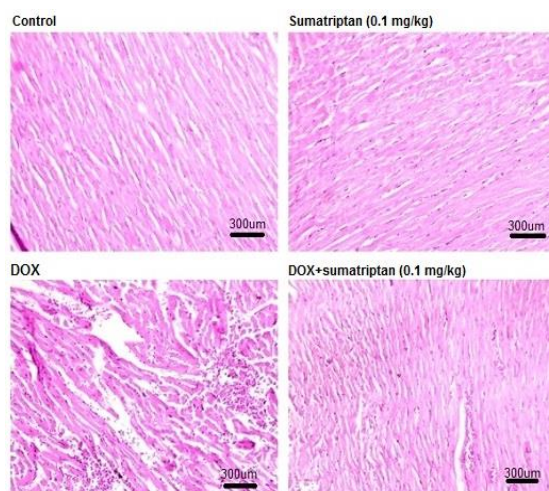


Figure 4. The effect of sumatriptan on histopathological changes in DOX-induced cardiotoxicity in rats. Control group with normal morphological appearance, sumatriptan (0.1 mg/kg) treated group with normal morphological appearance, DOX group with mononuclear inflammation, cytoplasmic vacuolization, tissue edema, and cardiomyocytes disarrangement. In the DOX+sumatriptan (0.1 mg/kg) treated group, mild mononuclear inflammation, cytoplasmic vacuolization, and cardiac damage were shown (Magnification $\times 200$)

Discussion

Results of the present study demonstrated that repetitive administration of lower doses of sumatriptan (0.1 mg/kg i.p) is associated with significant protective effects against doxorubicin-induced cardiac toxicity through reduction of weight loss and mortality rate, suppression in TNF- α and MDA concentration, and improvement in cardiac function. Also, cardiac histopathological damages considerably improved after administration of 0.1 mg/kg sumatriptan in this model.

Clinical application of doxorubicin is limited majorly due to its cardiotoxicity and nephrotoxicity. Rossi *et al.*, introduced DOX-induced cardiotoxicity by engaging an experimental model (4). DOX-induced cardiotoxicity was confirmed according to histological changes, decreasing papillary muscle stimulation threshold, and changes in ECG parameters. Generation of oxygen free radicals and lipid peroxidation are among pivotal molecular mechanisms contributing to DOX-induced cardiotoxicity that subsequently leads to the formation of pro-inflammatory cytokines such as TNF- α and increased level of oxidative mediator such as MDA, and also depletion of antioxidant enzymes such as SOD (27,28).

5-Hydroxytryptamine (5-HT), as a monoamine messenger derived from amino acid tryptophan, plays a pivotal role in many biological conditions (12). Physiological functions of 5-HT_{1B/D} depend on receptor subtypes located in different organs. (13). These presynaptic receptors are involved in decrease of production of proinflammatory factors. Recently, protective effects of sumatriptan in other conditions besides migraines have received a great deal of attention (22,29). In line with the literature, in the present study, the cumulative treatment of doxorubicin (15 mg/kg) was associated with cardiotoxicity and weight loss. DOX mimics some effects of cancer cachexia and reduces the body fat and skeletal muscle mass (30). It has been reported that bodyweight loss is a strong prognostic factor for DOX-induced toxicity. DOX administration is associated with skeletal muscle atrophy and reduction of lean body mass (31). However, the administration of sumatriptan effectively prevented doxorubicin-induced weight loss and mortality in rats.

The causes of animal death were direct toxic effects on intestinal mucosa as mucositis and acute myelosuppression (1,32). Congestive heart failure and nephropathy are the most important contributions to the cause of death (4,32-34). Our study showed the preventive effect of sumatriptan on the reduction of

mortality rate.

Our results on isolated papillary muscle evaluation exhibited that DOX-treated rats showed a decline in contractile force of myofiber and enhanced stimulation threshold of papillary muscles. Also, sumatriptan could prevent the heart from this negative effect of DOX on papillary muscle contractility. On the other hand, doxorubicin causes QT prolongation, and QT interval prolongation can be a good predictor of ventricular arrhythmias (35). We demonstrated that ECG parameters showed a significant increase in the duration of QT interval, QRS complex, and PR interval in DOX-treated rats. It has been described that connexin 43 (Cx43), a transmembrane protein, is a gap junction protein that has a crucial role in electrical signal communication between myocytes. Reduction in expression or degradation of gap junctions (Cx43) between myocytes is one of the important mechanisms of the ECG alteration in doxorubicin-induced cardiotoxicity (36-38). In this study, pretreatment of animals with sumatriptan caused improvement in ECG parameters and papillary muscle dysfunction.

Results of the histopathological studies also confirmed cardiotoxicity caused by cumulative treatment of DOX so that severe morphological changes were observed in cardiac tissue, including cytoplasmic vacuolization, myofibril loss, and leukocytes infiltration. It has been shown that tissue damage could be due to the induction of myocyte necrosis (39,40). Again myocardial injuries were considerably improved by the administration of the lower dose of sumatriptan, representing its beneficial property against doxorubicin-induced cardiotoxicity.

A large body of evidence shows that the administration of antioxidant agents attenuates DOX-induced cardiac dysfunction (41,42). Sumatriptan exerts its properties mainly via free radical scavenging and activation of the antiinflammatory pathway (19,20). Ikeda *et al.*, in an in-vitro study, showed direct scavenging activity of sumatriptan on superoxide and nitric oxide radicals using Electron Spin Resonance (ESR) spectroscopy (20). Similarly, Sheibani *et al.*, in a study on myocardial ischemia/reperfusion injury, provided evidence regarding the antiinflammatory and antioxidative activity of sumatriptan in this dose range (18).

In line with previous studies, our biochemical investigation provided remarkable results regarding cardio-protective effects of sumatriptan that could be mediated through increasing antioxidative and

antiinflammatory capacity as confirmed by a reduction in the levels of MDA and TNF- α and improvement the SOD level compared to the DOX-treated group. We suggest that treatment with sumatriptan exhibits antiinflammatory and antioxidative effects through decreasing TNF- α and MDA production. However, higher doses (1 and 3 mg/kg) of sumatriptan showed destructive effects. The present study highlights the notion that sumatriptan is a compound with a narrow therapeutic index and needs dose monitoring (therapeutic dose monitoring) to achieve the protective effects. Our previous studies with 0.3 mg/kg of sumatriptan in rat model of myocardial ischemia/reperfusion injury and also another study regarding the anti-pruritic effects of sumatriptan in chloroquine-induced scratching at doses of 0.1 and 0.3 mg/kg have shown that sumatriptan could exert both protective and destructive effects. While lower doses of sumatriptan are protective via antioxidative and antiinflammatory mechanisms (17,18,۴۳), higher dose are suggested to be associated with worsening cardiac function and myocardial ischemia through its predominant vasoconstrictive property (18,۴۴).

In summary, this study suggests that sumatriptan pretreatment could alleviate the cardiotoxicity and morphological changes induced by a cumulative dose of doxorubicin. It seems that these effects of lower doses of sumatriptan could mediate through its antiinflammatory and antioxidative properties.

Acknowledgements

This study was supported by grants from the Experimental Medicine Research Center, Tehran University of Medical Sciences (97-03-158-38190), from the Iran National Science Foundation (Grant number 96002757), and National Institute for Medical Research Development (NIMAD, Grant number: 958842).

References

- Hortobagyi G. Anthracyclines in the treatment of cancer. *Drugs* 1997;54:1-7.
- Singal PK, Iliskovic N. Doxorubicin-induced cardiomyopathy. *N Engl J Med* 1998;339:900-5.
- Von Hoff DD, Layard MW, Basa P, Davis Jr HL, Von Hoff AL, Rozenzweig M, et al. Risk factors for doxorubicin-induced congestive heart failure. *Ann Intern Med* 1979;91:710-7.
- Rossi F, Filippelli W, Russo S, Filippelli A, Berrino L. Cardiotoxicity of doxorubicin: effects of drugs inhibiting the release of vasoactive substances. *Pharmacol Toxicol* 1994;75:99-107.
- Khalilzadeh M, Abdollahi A, Abdolahi F, Abdolghafari AH, Dehpour AR, Jazaeri F. Protective effects of magnesium sulfate against doxorubicin-induced cardiotoxicity in rats. *Life Sci* 2018;207:436-41.
- Maia TN, Araujo GBRd, Teixeira JAC, Alves Junior EdD, Dias KP. Cardiotoxicity of doxorubicin treatment and physical activity: A systematic review. *Int J Cardiovasc Sci* 2017;30:70-80.
- Ojha S, Al Taei H, Goyal S, Mahajan UB, Patil CR, Arya D, et al. Cardioprotective potentials of plant-derived small molecules against doxorubicin associated cardiotoxicity. *Oxid Med Cell Longev* 2016;2016:5724973.
- Lehenbauer Ludke AR, Al-Shudiefat AA, Dhingra S, Jassal DS, Singal PK. A concise description of cardioprotective strategies in doxorubicin-induced cardiotoxicity. *Can J Physiol Pharmacol* 2009;87:756-63.
- Pecoraro M, Del Pizzo M, Marzocco S, Sorrentino R, Ciccarelli M, Iaccarino G, et al. Inflammatory mediators in a short-time mouse model of doxorubicin-induced cardiotoxicity. *Toxicol Appl Pharmacol* 2016;293:44-52.
- Nakamura Y, Kitamura Y, Sumiyoshi Y, Naito N, Kan S, Ushio S, et al. Involvement of 5-HT_{2A} receptor hyperfunction in the anxiety-like behavior induced by doxorubicin and cyclophosphamide combination treatment in rats. *J Pharmacol Sci* 2018;138:192-7.
- Kwatra M, Jangra A, Mishra M, Sharma Y, Ahmed S, Ghosh P, et al. Naringin and Sertraline Ameliorate Doxorubicin-Induced Behavioral Deficits Through Modulation of Serotonin Level and Mitochondrial Complexes Protection Pathway in Rat Hippocampus. *Neurochem Res* 2016;41:2352-66.
- Mohammad-Zadeh L, Moses L, Gwaltney-Brant S. Serotonin: a review. *J Vet Pharmacol Ther* 2008;31:187-99.
- Vanhoutte PM. Serotonin and the vascular wall. *Int J Cardiol* 1987;14:189-203.
- Haddadi NS, Ostadhadi S, Shakiba S, Afshari K, Rahimi N, Foroutan A, et al. Pharmacological evidence of involvement of nitric oxide pathway in anti-pruritic effects of sumatriptan in chloroquine-induced scratching in mice. *Fundam Clin Pharmacol* 2018;32:69-76
- Rutz S, Riegert C, Rothmaier AK, Buhot MC, Cassel JC, Jackisch R. Presynaptic serotonergic modulation of 5-HT and acetylcholine release in the hippocampus and the cortex of 5-HT_{1B}-receptor knockout mice. *Brain Res Bull* 2006;70:81-93.
- Araldi D, Ferrari LF, Levine JD. Gi-protein coupled 5-HT_{1B/D} receptor agonist sumatriptan induces type I hyperalgesic priming. *Pain* 2016;157:1773-82.
- Gooshe M, Ghasemi K, Rohani MM, Tafakhori A, Amiri

- S, Aghamollai V, et al. Biphasic effect of sumatriptan on PTZ-induced seizures in mice: Modulation by 5-HT_{1B/D} receptors and NOS/NO pathway. *Eur J Pharmacol* 2018;824:140-7.
18. Sheibani M, Faghir-Ghanesefat H, Dehpour S, Keshavarz-Bahaghighat H, Sepand MR, Ghahremani MH, et al. Sumatriptan protects against myocardial ischaemia–reperfusion injury by inhibition of inflammation in rat model. *Inflammopharmacology* 2019;27:1071-80.
 19. Vera–Portocarrero LP, Ossipov MH, King T, Porreca F. Reversal of inflammatory and noninflammatory visceral pain by central or peripheral actions of sumatriptan. *Gastroenterology* 2008;135:1369-78.
 20. Ikeda Y, Jimbo H, Shimazu M, Satoh K. Sumatriptan scavenges superoxide, hydroxyl, and nitric oxide radicals: in vitro electron spin resonance study. *Headache* 2002;42:888-92.
 21. Brahadeesh M, Suresha R. Screening of the drug Amiodarone for its Antiinflammatory potential in albino rats. *Int J Pharm Life Sci* 2016;7:5042-6.
 22. Dejban P, Rahimi N, Takzare N, Jahansouz M, Dehpour AR. Protective effects of sumatriptan on ischaemia/reperfusion injury following torsion/detorsion in ipsilateral and contralateral testes of rat. *Andrologia* 2019;51:e13358.
 23. Sheibani M, Nezamoleslami S, Faghir-Ghanesefat H, hossein Emami A, Dehpour AR. Cardioprotective effects of dapson against doxorubicin-induced cardiotoxicity in rats. *Cancer Chemother Pharmacol* 2020;85:563-71.
 24. Sumitra M, Manikandan P, Rao KVK, Nayeem M, Manohar BM, Puvanakrishnan R. Cardiorespiratory effects of diazepam-ketamine, xylazine-ketamine and thiopentone anesthesia in male Wistar rats-a comparative analysis. *Life Sci* 2004;75:1887-96.
 25. Faghir-Ghanesefat H, Rahimi N, Yarmohammadi F, Mokhtari T, Abdollahi AR, Ejtemaei Mehr S, et al. The expression, localization and function of $\alpha 7$ nicotinic acetylcholine receptor in rat corpus cavernosum. *J Pharm Pharmacol* 2017;69:1754-61.
 26. Ohkawa H, Ohishi N, Yagi K. Assay for lipid peroxides in animal tissues by thiobarbituric acid reaction. *Anal Biochem* 1979;95:351-8.
 27. Olson RD, Boerth RC, Gerber JG, Nies AS. Mechanism of adriamycin cardiotoxicity: evidence for oxidative stress. *Life Sci* 1981;29:1393-401.
 28. Xiong Y, Liu X, Lee CP, Chua BH, Ho YS. Attenuation of doxorubicin-induced contractile and mitochondrial dysfunction in mouse heart by cellular glutathione peroxidase. *Free Radic Biol Med* 2006;41:46-55.
 29. Haddadi NS, Foroutan A, Shakiba S, Afshari K, Ostadhadi S, Daneshpazhooh M, et al. Attenuation of serotonin-induced itch by sumatriptan: possible involvement of endogenous opioids. *Arch Dermatol Res* 2018;310:165-72.
 30. de Lima Junior EA, Yamashita AS, Pimentel GD, De Sousa LG, Santos RVT, Gonçalves CL, et al. doxorubicin caused severe hyperglycaemia and insulin resistance, mediated by inhibition in AMPk signalling in skeletal muscle. *J Cachexia Sarcopenia Muscle* 2016;7:615-25.
 31. Hiensch AE, Bolam KA, Mijwel S, Jeneson JA, Huitema AD, Kranenburg O, et al. Doxorubicin-induced skeletal muscle atrophy: Elucidating the underlying molecular pathways. *Acta Physiol (Oxf)* 2020;229:e13400.
 32. Hoekman K, van der Vijgh WJ, Vermorken JB. Clinical and preclinical modulation of chemotherapy-induced toxicity in patients with cancer. *Drugs* 1999;57:133-55.
 33. O’Connell JL, Romano MMD, Pulici ECC, Carvalho EE, de Souza FR, Tanaka DM, et al. Short-term and long-term models of doxorubicin-induced cardiomyopathy in rats: A comparison of functional and histopathological changes. *Exp Toxicol Pathol* 2017;69:213-9.
 34. Mitry MA, Edwards JG. Doxorubicin induced heart failure: Phenotype and molecular mechanisms. *Int J Cardiol Heart Vasc* 2016;10:17-24.
 35. Antoniou CK, Dilaveris P, Manolakou P, Galanakis S, Magkas N, Gatzoulis K, et al. QT prolongation and malignant arrhythmia: how serious a problem? *Eur Cardiol* 2017;12:112-20.
 36. Ribeiro-Rodrigues TM, Martins-Marques T, Morel S, Kwak BR, Girão H. Role of connexin 43 in different forms of intercellular communication–gap junctions, extracellular vesicles and tunnelling nanotubes. *J Cell Sci* 2017;130:3619-30.
 37. Pecoraro M, Sorrentino R, Franceschelli S, Del Pizzo M, Pinto A, Popolo A. Doxorubicin-mediated cardiotoxicity: role of mitochondrial connexin 43. *Cardiovasc Toxicol* 2015;15:366-76.
 38. Pecoraro M, Ciccarelli M, Fiordelisi A, Iaccarino G, Pinto A, Popolo A. Diazoxide improves mitochondrial connexin 43 expression in a mouse model of doxorubicin-induced cardiotoxicity. *Int J Mol Sci* 2018;19:757.
 39. Kelishomi RB, Ejtemaeemehr S, Tavangar SM, Rahimian R, Mobarakeh JI, Dehpour AR. Morphine is protective against doxorubicin-induced cardiotoxicity in rat. *Toxicology* 2008;243:96-104.
 40. Rahimi_Balaei M, Momeny M, Babaeikelishomi R, Mehr SE, Tavangar SM, Dehpour AR. The modulatory effect of lithium on doxorubicin-induced cardiotoxicity in rat. *Eur J Pharmacol* 2010;641:193-8.
 41. Oliveira PJ, Bjork JA, Santos MS, Leino RL, Froberg MK, Moreno AJ, et al. Carvedilol-mediated antioxidant protection against doxorubicin-induced cardiac mitochondrial toxicity. *Toxicol Appl Pharmacol*

- 2004;200:159-68.
42. Kaiserová H, Šimůnek T, Van Der Vijgh WJ, Bast A, Kvasničková E. Flavonoids as protectors against doxorubicin cardiotoxicity: role of iron chelation, antioxidant activity and inhibition of carbonyl reductase. *Biochim Biophys Acta* 2007;1772:1065-74.
43. Foroutan A, Haddadi NS, Ostadhadi S, Sistany N, Dehpour AR. Chloroquine-induced scratching is mediated by NO/cGMP pathway in mice. *Pharmacol Biochem Behav* 2015;134:79-84.
44. Mobasheran P, Rajai N, Kohansal P, Dehpour AR, Shafaroodi H. The effects of acute Sumatriptan treatment on renal ischemia/reperfusion injury in rat and the possible involvement of nitric oxide. *Can J Physiol Pharmacol* 2020;98:252-8.