

Nasolacrimal Duct Obstruction and Frequency of Agger Nasi Cell and other Anatomical Field Variations: A Controlled Study in Northern Iran

Hassan Behboudi¹, Abtin Heirati¹, Hengameh Behboudi¹, Maryam Akbari^{2,3}, Naghi Ramezani⁴, Makan Shalchizadeh^{2,3}, Abbas Hajian⁵, Shadman Nemati^{2,3}

¹ Department of Ophthalmology, Eye Research Center, Guilan University of Medical Sciences, Rasht, Iran

² Department of Otolaryngology and Head and Neck Surgery, Otorhinolaryngology Research Center, Guilan University of Medical Sciences, Rasht, Iran

³ School of Medicine, Guilan University of Medical Sciences, Rasht, Iran

⁴ Department of Radiology, Sepehr Radiology Center, Guilan University of Medical Sciences, Rasht, Iran

⁵ Department of General Surgery, Kashan University of Medical Sciences, Kashan, Iran

Received: 14 Oct. 2020; Accepted: 08 Mar. 2021

Abstract- In this study, we aimed to find the frequency of agger nasi cells (ANC) and their correlation with other anatomical anomalies in dacryocystorhinostomy (DCR) candidates, compared with a control group. The study was conducted on 42 patients with nasolacrimal duct obstruction who underwent DCR surgery. Also, 80 C.T. of healthy sex- and age-matched subjects were selected as the control group. Paranasal sinuses computed tomography scanning was performed preoperatively, and abnormalities including ANC, concha bullosa, osteomeatal complex disease (OMC), nasal septum deviation, and polyposis were investigated and registered. Radiologic findings showed ANC presence in 83.3% of cases, and frequency of concha bullosa was 23.8%, and OMC disease, septal deviation, and nasal polyposis recorded as 11.9%, 85.7%, and 14.3%, respectively. In the control group, ANC was found in 52 subjects (65%), and the difference was statistically significant ($P=0.036$). There was no significant correlation between the presence of ANC and the coexistence of other mentioned anatomical changes as attributing factors for NLD obstruction. The frequency of ANC was much higher in patients with NLD obstruction compared with the control group, but its association with other anomalies was non-significant.

© 2021 Tehran University of Medical Sciences. All rights reserved.

Acta Med Iran 2021;59(4):203-207.

Keywords: Agger nasi cells; Nasolacrimal duct obstruction; Dacryocystorhinostomy

Introduction

Almost all teardrops secreted by the lacrimal apparatus are located in the superolateral side of the orbit. Secreted tears produce a multifunctional shield on the cornea surface of the eyes. Then they transport via the punctum to the nasolacrimal duct (NLD), which conducts tears into the inferior meatus inside the nose. Therefore, any etiologic factor for excessive tear production and/or obstruction of NLD leads to epiphora, a sensation of watery eyes, and streaming tears on the face. Even with considering causes of production, the

most common cause of epiphora is NLD obstruction, either congenital or acquired etiologies including dacryocystitis, trauma, lacrimal plaques, neoplasms, aging, inflammatory disease, and sinonasal anomalies (1-3). There are various types of anatomical variants that may cause NLD obstruction and lead to epiphora. They are including OMC disease, ethmoidal opacity/sinusitis, concha bullosa, nasal septal deviation, and agger nasi cells (4,5). Because of the complexity of numerous adjacent structures and related function of soft and bony tissue, and also because of the limited space of the nasal vault, the little anatomical change of each part has a

Corresponding Author: Sh. Nemati

Department of Otolaryngology and Head and Neck Surgery, Otorhinolaryngology Research Center, Guilan University of Medical Sciences, Rasht, Iran

Tel: +98 133322524, Fax: +98 1333225242, E-mail address: drshadmannemati_ent@yahoo.com

Copyright © 2021 Tehran University of Medical Sciences. Published by Tehran University of Medical Sciences

This work is licensed under a Creative Commons Attribution-NonCommercial 4.0 International license (<https://creativecommons.org/licenses/by-nc/4.0/>). Non-commercial uses of the work are permitted, provided the original work is properly cited

negative effect on the function of others parts (3,4).

Agger nasi cell (ANC), located just anterior to the anterior-superior attachment of the middle turbinate and anterior, lateral, and inferior to the frontal recess, is an anatomical variation originating from pneumatization of anterior ethmoidal sinuses (3,4,6) (Figure 1). Thus enlargement of this potential space dislocates the attachment and position of the middle turbinate superomedial, leading to narrowing or obstruction of NLD and the frontal recess, that cause epiphora, and sinusitis, respectively (6). Previous studies reported the prevalence of ANC highly different, from 1.9% to 98.5% (7-9). ANC is a documented cause for unsuccessful external DCR surgery that requires revision internal or external approach DCR for NLD reopening (4,10). Concha bullosa usually originates from pneumatization of middle turbinate and then it develops in the superior and inferior turbinate respectively. This anatomical change occurs following ethmoidal aerated cells migration (6). OMC disease is a lesion arises from anterior edge of maxillary meatus expanding to the junction of ANC and middle turbinate. It locates anteriorly according to ethmoidal bulla and the other anterior ethmoidal sinuses (3,5).

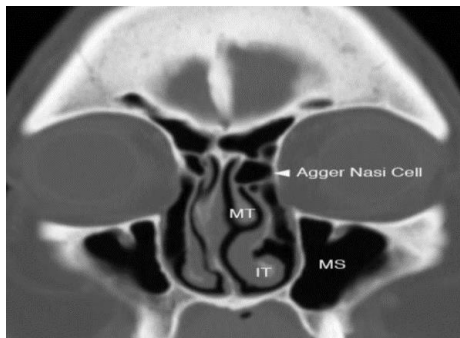


Figure 1. Coronal image with arrowhead showing Agger Nasi air cell. (MS: maxillary sinus, MT: middle turbinate, I.T.: inferior turbinate). (University of Washington Department of Radiology Seattle, Washington)

Preoperative computed tomography (C.T.) scan preferably in coronal view is the gold standard test for finding ANC (9,10). Although frequency of other sinonasal anomalies-mentioned above- in DCR candidates has been reported by many authors previously (4,10-14), but we found little data about association of coexistence of these anatomical changes in DCR candidates. Considering this issue, this study aimed to evaluate importance of presence of the ANC in association with finding of other anatomical variants (Concha bullosa, OMC, nasal septum deviation and

polyposis) that may lead to NLD obstruction and unfavorable outcome after DCR surgery.

Materials and Methods

This study was conducted in 42 cases of NLD obstruction, attending the Amiralmomenin University Hospital in Rasht, north of Iran. The research proposal, which was the thesis for the medical doctorate of H.B (for T.T Thesis No. 1393.1831.), approved by the Research Council and Ethics Committee of Guilan University of Medical Sciences.

From 90 adult patients with epiphora for at least three months that were a candidate for DCR procedure, eventually, 42 cases were selected randomly using random blocks, from March to December 2016. Inclusion criteria were diagnosis of NLD obstruction and age more than 18-year-old. NLD obstruction was diagnosed by naso-ophthalmic clinical examination and irrigation test. Irrigation test was performed with topical anesthesia, using saline 0.9%, and after ruling out dacryoliths-functional NLD. Patients with prior history of DCR procedure, naso-orbital trauma, and experience of sinonasal surgeries were excluded. A paranasal C.T. scan in coronal view was done for all the cases. Also, from more than 120 coronal C.T. scans of paranasal sinuses, 80 C.T. of healthy (without epiphora, nasal polyposis, or pieces of evidence of sinus surgery) sex- and age-matched subjects were selected as the control group.

Written informed consent was signed by all the cases. After evaluation of medical findings by an expert otolaryngologist, cases were prepared for the external-percutaneous-DCR approach with insertion of the silicon tube. Participants followed up three months after surgery, and surgical success was evaluated by tube removal and irrigation re-test and clinical outcome (i.e., recovery of epiphora). Demographic data, including age, gender, and race, clinical examination data before and after surgery, result of irrigation test, the success of surgery, and paranasal C.T. scan findings including existence and characteristics of ANC, concha bullosa, OMC, nasal polyposis, sinusitis, and nasal septal deviation were recorded. Based on radiologic measures, ANCs were categorized into two groups; small (<0.5 cm²) and large (≥ 0.5 cm²), and also, according to ANC expansion toward lacrimal sac (whether vertically or horizontally), these cells were also categorized in two coverage groups; low expansion-small ($<50\%$) and wide expansion-large ($\geq 50\%$). We also compared data in two age groups for analytic comparison: <40 years old

patients and ≥ 40 -year-old.

Statistical analysis

Data analysis was accomplished by SPSS v.21, using Chi-square and Fisher Exact test, and level of significance was considered as P less than 0.05. Descriptive data, including mean, standard deviations, mode, minimum and maximum in addition to numbers and percent for variables, was introduced in the form of a number (%) along with the text.

Results

Totally 42 patients with primary acquired NLD obstruction and candidates for DCR were enrolled in the study: thirty (71.4%) male, and twelve (28.6%) female, with a mean age of 58.6 ± 18.1 years (from 25 to 85-year-old). In the control group, 80 non-polyposis subjects with no history of sinonasal surgeries enrolled: fifty (62.5%) male and thirty (37.5%) female, with a mean age of 51.2 ± 17.3 (20 to 77-year-old). There was no significant difference between case and control groups in the sex ratio and mean age ($P=0.83$, and $P=0.72$, respectively).

Based on paranasal C.T. reports, 35 of DCR cases

(83.33%) represented ANC and the 7 cases (16.66%) had none. In the control group, ANC was found in 52 subjects (65%), and the difference was statistically significant between the case and control groups ($P=0.036$). Radiologic measures revealed the prevalence of small-sized-low expanded-ANCs in 18 (51.4%) and large-wide expanded-one in 17 (48.6%) cases, and in the control group, 53.9% (28 subjects) was a large size, with no significant difference ($P>0.05$). Considering gender, also no significant differences were noticed in the presence of ANC ($P=0.66$), as 9 (75%) and 26 (86.6%) of females and males had ANC, respectively. Also, according to the age of our cases, there was no significant difference between age groups (below and ≥ 40 -year-old) in the presence of ANC ($P=0.67$). Table 1 manifests study results in terms of prevalence and accompaniment of other anatomical variables, including concha bullosa, OMC disease, sinusitis, nasal polyp, and septal deviation in two groups. In the control group (with no polyposis according to our exclusion criteria), the frequency of concha bullosa was 51.25% (41 subjects: 51.22% bilateral), and frequency of septal deviation and OMC disease were 82.5% and 18.75%, respectively. Ten out of 80 subjects (12.5%) showed mild degrees of sinusitis.

Table 1. Frequency of anatomical variables in DCR candidates (n=42) and control group (n=80)

Anatomical variable	Radiologic findings			
	DCR candidates		Control group	
	Presence n (%)	Absence n (%)	Presence n (%)	Absence n (%)
*ANC	35 (83.33)	7 (16.66)	52 (65)	28 (35)
Concha bullosa	10 (23.8)	32 (76.2)	41 (51.25)	39 (48.75)
**OMC disease	5 (11.9)	37 (88.1)	15 (18.75)	65 (81.25)
Sinusitis	4 (9.5)	38 (90.5)	10 (12.5)	70 (87.5)
Nasal polyp	6 (14.3)	36 (85.7)	0	80 (100)
Septal deviation	36 (85.7)	6 (14.3)	66 (82.5)	14 (17.5)

*Agger nasi cell

**osteomeatal complex

Data analysis showed no correlation between the presence of ANC and any other anatomical changes in patients with acquired NLD obstruction ($P>0.05$). In the case of the simultaneous presence of ANC and nasal septum deviation, intragroup study analysis revealed

difference neither for 15 (83.3%) left deviations nor for 14 (77.8%) right ones ($P=0.35$) (Figure 2).

In follow-up three months after surgery, silicon tube removed and irrigation re-test showed successful outcome for all 42 (100%) patients who underwent

external DCR approach.

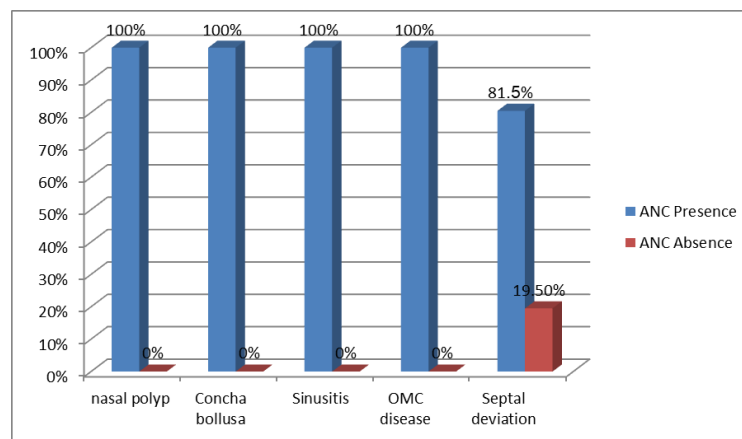


Figure 2. Frequency of Agger Nasi Cell (ANC) distribution according to the presence of various radiological findings in candidate patients of dacryocystorhinostomy. The ordinate axis consists of the percentage of patients

Discussion

Epiphora is a common symptom that distracts normal daily visual function and even may become life-threatening in special situations. Acquired unresolved NLD obstruction is a well-known reason for epiphora originating from changes in the nasal cavity and attributed viscera. Although about half of etiologic factors for NLD are unknown (15) but many studies pointed to anatomical sino-nasal anomalies for acquired NLD obstruction, including the presence of ANC (2,4-6,8,16-20). ANC makes obstruction by affecting the proximal intranasal portion of NLD and also the lacrimal sac. The prevalence of ANC in previous studies varied widely so that it was reported from less than 2% (7,8) to near 100% (9). The current study showed 81% of Iranian patients had positive radiologic findings for ANC Presence, and among them, 38% of cells were large and covered 50% or more volume of the lacrimal sac. Although some reports implied more involvement of females than of males in case of acquired NLD obstruction (3), our data supported equality in this issue. Evidence for concha bullosa was found in about 24% of paranasal C.T. reports in the cases group, while other studies revealed it in 36% of cases (4). We found no relation between the presence of concha bullosa and ANC that was compatible with other reports (5,6,16). The frequency of OMC disease in our study was about 12% of cases; however, it was 14-35% in previous studies (5). OMC disease had no correlation with ANC in the current assessment. Similar result was found considering sinusitis and nasal polyposis. There is no evidence of a relationship between the presence of ANC

and sinusitis or nasal polyposis (20,21). Our finding was consistent with the explanation of others that sinusitis alone was not an obstructive factor for NLD dysfunction. In the case of nasal septum deviation, about 86% of our study participants were involved. Although some reports showed more susceptibility for NLD obstruction, preferably in left deviations (3), that was not in agreement with our finding. Also, results showed no difference between ANC and the presence or absence of septal deviation. Some authors believed that ANC is a causative factor for unsuccessful DCR surgery; however, some others disagreed (4,10). Our study did not reveal any adverse effect of ANC presence on DCR outcome, and the success rate after 3-months follow-up in our patients was 100%. This controversy may be due to our small sample size; although, some other factors, such as surgeon's skill, quality of applied material, and special attention to anatomical anomalies regarding C.T. scan findings, may be important. The latter is a clue reason for performing paranasal C.T. scanning preoperatively, as the gold standard test to investigate field anomalies (5).

The study assessed acquired anatomical changes in the field of nose and NLD without considering chronic hypersensitivity disorders in participants. To achieve reliable results to generalize to the general population, more studies with a larger sample size should be done.

Radiologic-based pieces of evidence in patients with acquired NLD obstruction showed different sinonasal anatomical and pathological anomalies, including ANC, concha bullosa, OMC disease, nasal septum deviation, and polyposis. These anatomical anomalies may induce NLD obstruction alone or along with each other.

However, according to the scope of the study, we found no association between the presence of ANC and the other mentioned pathologies. Scanning of the paranasal field with the C.T. approach is a precise guide for surgery preoperatively. Prospective studies with a larger sample size suggested achieving more clear findings.

Acknowledgments

Our special thanks to Hedieh Ramezani (from Otorhinolaryngology Research Center) and also for Research and Technology Office of Guilan University of Medical Sciences, Rasht, Iran, for their assists in performing this research.

References

- Hur MC, Jin SW, Roh MS, Jeong WJ, Ryu WY, Kwon YH, et al. Classification of lacrimal punctal stenosis and its related histopathological feature in patients with epiphora. *Korean J Ophthalmol* 2017;31:375-82.
- Holds JB, Chang WH, Durairaj VD. *Orbit, Eyelids, and Lacrimal System Basic and Clinical Science Course, Lifelong education for the ophthalmologist revised*. New York: Amer Academy of Ophthalmology 2013;P124-211.
- Singh S, Alam MS, Javed Ali M, Naik MN. Endoscopic intranasal findings in unilateral primary acquired nasolacrimal duct obstruction. *Saudi J Ophthalmol* 2017;31:128-30.
- Liang J, Hur K, Merbs SL, Lane AP. Surgical and anatomic considerations endoscopic revision of failed external dacryocystorhinostomy. *Otolaryngol Head Neck Surg* 2014;150:901-5.
- Kaplan M, Fiahin E, Gürsel AO. Examination of lateral nasal wall pathologies associated with distal lacrimal duct obstruction. *ENT Updates* 2015;5:68-71.
- Kantarci M, Karasen RM, Alper F, Onbas O, Okur A, Karaman A. Remarkable anatomic variations in paranasal sinus region and their clinical importance. *Eur J Radiol* 2004;50:296-302.
- Aramani A, Karadi RN, Kumar S. A study of anatomical variations of osteomeatal complex in chronic rhinosinusitis patients-CT findings. *J Clin Diagn Res* 2014;8:KC01-4.
- Liu X, Zhan G, Xu G. Anatomical variations of osteomeatal complex and correlation with chronic sinusitis: C.T. evaluation. *Chin J Otorhinolaryngol Head Neck Surg (Zhonghua Er Bi Yan Hou Ke Za Zhi)* 1999;34:143-6.
- Bolger WE, Butzin CA, Parsons DS. Paranasal sinus bony anatomic variations and mucosal abnormalities: C.T. analysis for endoscopic sinus surgery. *Laryngoscope* 1991;101:56-64.
- Eyigör H, Unsal AI, Unsal A. The role of accompanying sinonasal abnormalities in the outcome of endonasal dacryocystorhinostomy. *Am J Rhinol* 2006;20:620-4.
- Gökçek A, Argin MA, Altintas AK. Comparison of failed and successful dacryocystorhinostomy by using computed tomographic dacryocystography findings. *Eur J Ophthalmol* 2005;15:523-9.
- Woo KI, Maeng HS, Kim YD. Characteristics of intranasal structures for endonasal dacryocystorhinostomy in Asians. *Am J Ophthalmol* 2011;152:491-8.
- Soyka MB, Treumann T, Schlegel CT. The Agger Nasi cell and uncinat process, the keys to proper access to the nasolacrimal drainage system. *Rhinology* 2010;48:364-7.
- Zhang L, Han DM, Ge WT, Zhou B, Xian JF, Liu ZY, et al. Anatomical and computed tomographic analysis of the interaction between uncinat process and agger nasi cells. *Otolaryngol Head Neck Surg (Zhonghua Er Bi Yan Hou Tou Jing Wai Ke Za Zhi)* 2005;40:912-6.
- Al-Shaikh S, Javed F, Fincham G, Latif M, Bhutta M. U.K. survey of the present role of ear, nose and throat surgeons in lacrimal surgery. *Ann R Coll Surg Engl* 2010;92:583-6.
- Onwuchekwa RC, Alazigha N. Computed tomography anatomy of the paranasal sinuses and anatomical variants of clinical relevant in Nigerian adults. *Egypt J Ear Nose Throat Allied Sci* 2017;18:31-8.
- Dua K, Chopra H, Khurana AS, et al. C.T. scan variations in chronic sinusitis. *Indian J Radiol Imaging* 2005;15:315-20.
- Rashid A, Deep B, Wameedh A, Al-Badaai Y, Sawhney S. Clinically significant anatomical variants of the paranasal sinuses. *Oman Med J* 2014;29:110-13.
- Erfanian Salim R, Mohammadi S. Results of Endoscopic Endonasal Dacryocystorhinostomy; Necessity of Teamwork and Patient Selection; *Med Hypothesis Discov Innov Ophthalmol* 2015;4:114-9.
- Watkins LM, Janfaza P, Rubin PA. The evolution of endonasal dacryocystorhinostomy. *Surv Ophthalmol* 2003;48:73-84.
- Dinis PB, Matos TO, Angelo P. Does Sinusitis Play a Pathogenic Role in Primary Acquired Obstructive Disease of the Lachrymal System? *Otolaryngol Head Neck Surg* 2012;148:685-8.