

# Liver Stiffness Measurement by Fibroscan in Patients With Hepatitis B

Ali Bahari<sup>1,2</sup>, Seyed Mahmoud Hoseinian<sup>1,2</sup>, Abbas Esmaealzadeh<sup>1,2</sup>, Azita Ganji<sup>1</sup>, Zohre Bari<sup>2</sup>

<sup>1</sup> Gastroenterology and Hepatology Research Center, Mashhad University of Medical Sciences, Mashhad, Iran

<sup>2</sup> Department of Internal Medicine, School of Medicine, Mashhad University of Medical Sciences, Mashhad, Iran

Received: 21 Jun. 2020; Accepted: 14 Nov. 2020

**Abstract-** About 6 percent (2%-7%) of the world's population is chronically infected by the hepatitis B virus (HBV). The role of fibroscan for fibrosis assessment in HBV patients has not been widely studied. The present study was designed for the assessment of hepatic fibrosis by fibroscan in HBV positive patients. This is a cross-sectional study with two groups of case and control. According to the physical examination, lab data, abdominal ultrasound, and hepatitis viral load, the case group was categorized into three subgroups: inactive carrier, chronic hepatitis, and cirrhosis. The Control group was selected from a healthy population of 145 HBV patients, and 370 healthy persons entered the study. The case group included 35 inactive carriers, 63 chronic hepatitis B, and 47 cirrhotic patients, and their mean amount of fibrosis (measured by fibroscan) was 6.169 kpa, 7.758 kpa, and 24.0255 kpa, respectively. Also, the mean amount of fibrosis was 5.5510 (SD=2.43) in the control group. There was a statistically significant difference between cirrhotic patients and other groups ( $P<0.001$ ). Also, a strong association between viral load and fibrosis degree was observed in chronic hepatitis B patients ( $P<0.001$ ,  $R^2=0.7811$ ). Fibroscan is a novel instrument for the estimation of the liver fibrotic stage in HBV cirrhotic patients.

© 2020 Tehran University of Medical Sciences. All rights reserved.

*Acta Med Iran* 2020;58(11):577-581.

**Keywords:** Fibroscan; Chronic hepatitis B; Cirrhosis; Inactive carrier

## Introduction

Viral hepatitis is an important medical issue in the world. About two billion people were infected by HBV, and two hundred forty million people (approximately 6% of the world's population) are chronically infected by HBV (1,2).

Most of these patients are infected just by HBV, especially in the Asia and Sub-Saharan Africa regions. Patients suffer from long-term problems, such as cirrhosis, liver failure, and hepatocellular carcinoma (HCC) (3,4). HBV infection is the main reason for the occurrence of HCC in some countries such as Iran so that about 80% of Iranian HCC patients have positive serologic markers of HBV infection (5).

The fibrotic stage of the liver is an important factor for the determination of liver disease severity. Although the liver biopsy (LB) is a gold standard technique for assessment of liver fibrosis, it is an invasive technique and has several disadvantages, such as pain, bleeding, infection, high cost, and even mortality. In addition, sampling errors and intra- and inter-observer variations cause doubt in the accuracy of

assessing fibrosis (6). Therefore, noninvasive methods are developing rapidly to assess liver fibrosis (7).

Liver stiffness measurement (LSM) using fibroscan is a non-invasive, rapid, quantitative, and low-cost transient elastographic method for assessing the degree of liver fibrosis (8). Results are reported by Kilopascals (Kpa) and range from 2.5 to 75 Kpa (9).

The efficacy of transient elastography is validated in patients with chronic hepatitis C and fatty liver, but fewer data are available about patients with other forms of liver disease, particularly HBV positive patients (10,11).

Accordingly, it is important to assess the diagnostic accuracy for predicting significant fibrosis or cirrhosis among patients with HBV infection. The aim of this study was the assessment of fibrosis level (measured by fibroscan) in HBV patients and their control group. This study was approved by the "ethical committee" of our university.

## Materials and Methods

This is a cross-sectional study that included two

**Corresponding Author:** S.M. Hoseinian

Gastroenterology and Hepatology Research Center, Mashhad University of Medical Sciences, Mashhad, Iran  
Tel: +98 9155018563, Fax: +98 5138525301, E-mail address: HoseinianM942@mums.ac.ir

## Fibroscan in hepatitis B

groups of cases and controls. All of the participants had a BMI of less than 30 and did not have a medical history of heart failure. In the case group, the authors enrolled individuals with positive HBsAg (at least for six months). These patients were divided into three sub-groups; 1- inactive carriers 2- chronic hepatitis and 3- cirrhosis (according to physical examination, liver function tests (aminotransferases, Albumin, and INR), complete blood count (CBC), abdominal ultrasound, and HBV viral load).

Inactive carriers had: positive HBsAg, normal alanine transferase (ALT) levels (<40) for at least two times, negative HBe-Ag, and viral load less than 2000 IU/ml (in the absence of cirrhosis and chronic hepatitis criteria). Chronic hepatitis B patients had positive HBsAg (at least for six months), ALT levels <5 times the normal upper limit, INR <1.2, platelet count more than 150000/ml, and normal echogenicity of the liver in abdominal ultrasound imaging without cirrhosis indicators (ascites, esophageal varix).

Cirrhotic patients had ALT levels <5 times the normal upper limit, thrombocytopenia (platelet count less than 150000/ml), INR >1.2, coarse liver echogenicity in ultrasound imaging, sometimes accompanied by esophageal varix or ascites.

The control group included healthy persons with negative HBS-Ag. The exclusion criteria for both groups were: being infected with other viral hepatitis such as hepatitis C, autoimmune or drug-induced hepatitis, liver cancer or surgery, and liver or heart failure

In order to measure liver stiffness, Fibroscan (Echo Sens, Paris, France) and M probe attachment was used. A vibration of mild amplitude and low frequency was transmitted from the vibrator placed on the body surface

toward the liver through the intercostal space. The vibration induces an elastic shear wave that propagates through the liver tissue (12,13). The pulse-echo ultrasound acquisitions follow the propagation of the shear wave and determine its velocity. The velocity is directly according to tissue stiffness; the harder tissue increases, the shear wave propagates. LSM was calculated from velocity and expressed in kpa (14).

It should be mentioned that the Fibroscan operator in this study was a gastroenterologist who had the experience of performing more than 500 fibroscans.

### Statistical analysis

In this study, we used descriptive analysis such as mean±SD, inter-quartile range (IQR), and 95% confidence intervals (CI) for fibrosis results that were measured by fibro scan. Also, T independent test, Kruskal-Wallis rank test, and linear regression analyses were used as appropriate. Statistical significance was assumed if  $P < 0.05$ . All reported P-values were two-sided. Statistical analyses were performed using STATA (Version 11.1, SE, Texas).

### Results

There were 145 HBV positive patients in the case and 370 healthy persons in the control groups. The case group included 35 inactive carriers, 63 chronic hepatitis B, and 47 cirrhotic patients. Also, 98 patients in the case group were male (70%), and 47 were female (30%). The Control group had 203 males (55%) and 167 females (45%). Some of these characteristics are shown in Table 1.

**Table 1. Baseline details in subgroups of the study.**

Feature	Controls N=370	Cases N=145		
		Inactive carrier	Chronic hepatitis	cirrhosis
Age (year)	35.50 ± 15.92	40 ± 8.03	44.80 ± 13.9	53.13 ± 13.5
Weight (Kg)	75.05	75.31	71.07	75.34
Height (cm)	164.4	170.76	168.5	166.85
Waist circumference (cm)	94.75	93.28	91.8	95.72
Body mass (kg/cm <sup>2</sup> )	27.63	25.82	25.03	27.06
Viral load (copy/mL)	0	2061.013	80170910	1244440

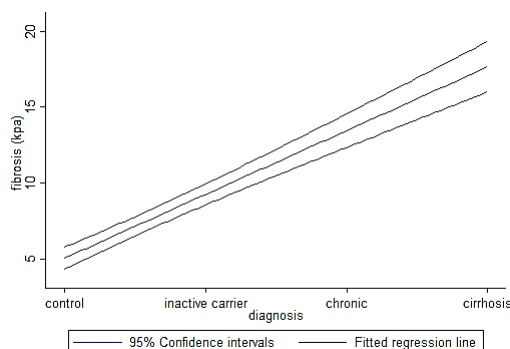
Means of measured fibrosis by fibroscan for inactive carriers of HBV, chronic HBV, and cirrhotic patients were 6.16±2.66, 7.75873±7.65, and 24.02558±19.88 Kpa, respectively. In the control group, the mean

fibrosis level was 5.551081±2.43 Kpa. Interquartile ranges and 95% confidence intervals for means are shown in Table 2. Also, differences in the mean levels are shown in graph 1 and graph 3.

**Table 2. Descriptive analysis for fibrosis by fibroscan method.**

	Mean	IQR	95% CI
<b>Inactive carrier</b>	6.16 ±2.66	5.1-6.5	5.24 - 7.05
<b>Chronic</b>	7.77903 ± 7.65	5.3-7.3	5.8 - 9.7
<b>Cirrhosis</b>	24.0255± 19.88	9.4 – 32.8	17.9 – 30.1
<b>Control group</b>	5.551081±2.43	4.4- 6.3	5.302- 5.799

IQR: Interquartile range



**Graph 1.** Fibroscan result of each subgroup (with 95% CI)

According to Table 3 (Kruskal-Wallis rank test), a significant association is seen between the progression of liver disease (inactive carrier, chronic HBV, and

cirrhotic patients, respectively) and the mean degree of fibrosis.

**Table 3. Kruskal-Wallis rank test analysis between mean fibrosis by fibroscan in HBV groups**

Group	number	mean ranks	P	$\chi^2$
<b>Inactive carrier</b>	35	9288.00	0.001	127.74
<b>Chronic</b>	63	19550.00		
<b>Cirrhosis</b>	43	20549.50		
<b>Control</b>	370	81428.50		

\* statistical significance was <0.01

In multiple comparisons (Post Hoc) by Dunnett T3 test for equal variance groups, the mean liver stiffness in cirrhotic patients was statistically higher than the other groups (control participants, inactive carriers and chronic hepatitis patients) ( $P<0.001$ ,  $\chi^2= 127.74$ ,  $df=3$ , in Table 4).

According to Table 5 and graph 2, there was significant accordance between HBV viral load and liver stiffness measurement by fibroscan in chronic hepatitis B patients ( $P<0.001$ ). A similar relationship was not detected in other subgroups ( $P<0.378$  for inactive carrier and  $P<0.121$  for cirrhosis).

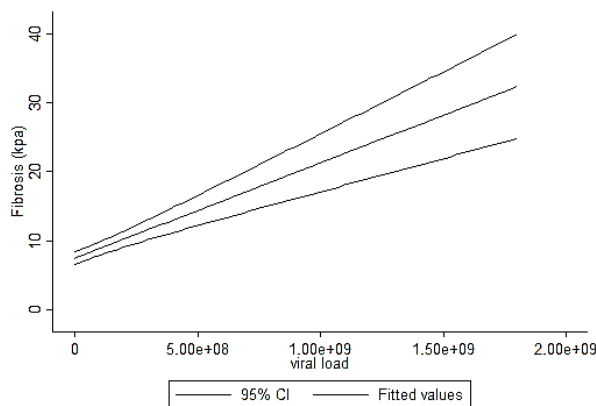
**Table 4. Multiple comparisons of mean liver stiffness in hepatitis B patients**

Group 1	Group 2	Mean ranks	P
<b>Inactive carrier</b>	Chronic	-1.598	0.579
	Cirrhosis	-17.86	0.001
	Control	0.60	0.723
<b>Chronic</b>	Cirrhosis	-16.26	0.001
	Control	2.20	0.147
<b>Cirrhosis</b>	Control	18.47	0.001

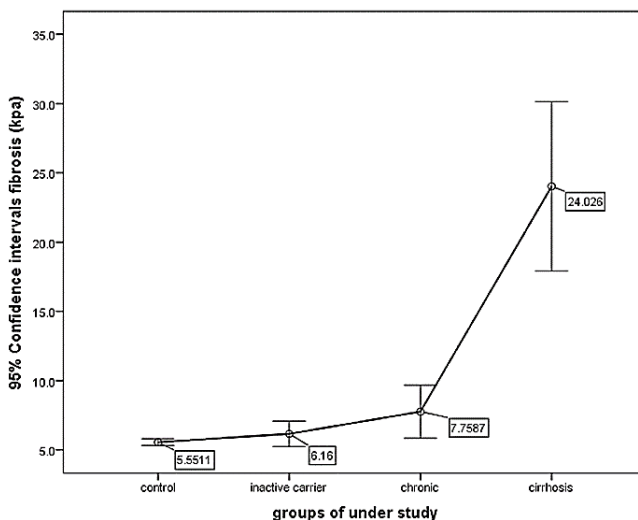
**Table 5. Linear regression analysis between fibrosis score by fibroscan and viral load in chronic HBV**

Fibrosis (kpa)	Coefficient	SE	P	
<b>Viral load(copy)</b>	$14 \times 10^{-9}$	$133 \times 10^{-11}$	0.001**	$R^2_{\text{adjusted}} = 0.7796$
<b>Constant term</b>	7.197045	0.4345289	0.001**	

**Fibroscan in hepatitis B**



(5.00e+08=  $5 \times 10^{+8}$ ), (1.00e+09=  $1 \times 10^{+9}$ ), (1.50e+09=  $1.5 \times 10^{+9}$ ), (2.00e+09=  $2 \times 10^{+9}$ )  
**Graph 2.** Linear association between viral load and fibrosis in chronic HBV subgroup



**Graph 3.** 95% CI for mean fibrosis in HBV and control group

**Discussion**

Fibroscan is progressively used for the evaluation of liver stiffness in several liver diseases. Up to now, some studies have been performed on HBV positive patients. However, they have mostly used a liver biopsy to be compared with fibroscan results.

In our study, the classification of HBS-Ag positive patients was different from other studies (15-17). Patients were classified into three subgroups: inactive carriers, chronic hepatitis B, and cirrhotic patients. This classification was not based on liver biopsy and was based on physical examination, liver function test, complete blood count (CBC), abdominal ultrasound, and HBV viral load.

We also had a control group that was included a

healthy population. Our patients had normal ALT or elevated ALT less than five times the normal upper limit. The mean of fibrosis results were 5.55, 6.16, 7.77 Kpa, and 24 Kpa in the control group, inactive carriers, chronic hepatitis, and cirrhotic patients, respectively. Although high ALT levels can alter the results of fibroscan, the EASL-ALEH clinical practice guideline recommends that fibroscan should not be done for patients with ALT levels higher than ten times of normal upper limit (18).

The interquartile ranges (IQR) were 4.4-6.3, 5.1-6.5, 5.3-7.3, and 9.4-32.8 in the control group, inactive carriers, chronic hepatitis B, and cirrhotic patients, respectively.

The 95% confidence intervals (95% CI) were 5.3-5.79, 5.24-7.05, 5.8-9.7, and 17.9-30.1 in the control

group, inactive carriers, chronic hepatitis B, and cirrhotic patients, respectively.

There was a significant association between mean liver stiffness and progression of HBV-related liver disease in this stud, and the mean liver stiffness in cirrhotic patients was significantly higher than other groups ( $P < 0.001$ ).

The relationship between HBV viral load and liver fibrosis is controversial. We detected a directed linear relationship between HBV viral load and liver stiffness measurement in the chronic hepatitis B group (but not in inactive carriers and cirrhotic patients).

In conclusion, Fibroscan is a novel and strong instrument for the estimation and determination of the liver fibrotic stage in HBV cirrhotic patients. This study detected a linear association between viral load and fibrosis in chronic hepatitis B patients.

## References

- Gall SA. hepatitis B virus immunization today. *Infect Dis Obstet Gynecol* 2001;9:63-4.
- Nabulsi MM, Araj GF, Nuwayhid I, Ramadan M, Ariss M. Prevalence of hepatitis B infection markers in Lebanese children: the need for an expanded programme on immunization. *Epidemiol Infect* 2001;126:285-9.
- Mast EE, Margolis HS, Fiore AE, Brink EW, Goldstein ST, Wang SA, et al. A comprehensive immunization strategy to eliminate transmission of hepatitis B virus infection in the United States: recommendations of the Advisory Committee on Immunization Practices (ACIP) part I: immunization of infants, children, and adolescents. *MMWR Recomm Rep* 2005;54:1-31.
- Parkin DM, Bray F, Ferlay J, Pisani P. Estimating the world cancer burden: Globocan 2000. *Int J Cancer* 2001;94:153-6.
- Merat S, Malekzadeh R, Rezvan H, Khatibian M. Hepatitis B in Iran. *Arch Iran Med* 2000;3:192-201.
- Vergniol J, Foucher J, Terrebbonne E, Bernard PH, Bail B, Merrouche W, et al. Noninvasive tests for fibrosis and liver stiffness predict 5-year outcomes of patients with chronic hepatitis C. *Gastroenterology* 2011;140:1970-9, 1979.e1-3.
- Ratziu V, Charlotte F, Heurtier A, Gombert S, Giral P, Bruckert E, et al. Sampling variability of liver biopsy in nonalcoholic fatty liver disease. *Gastroenterology* 2005;128:1898-906.
- Sharma P, Dhawan S, Bansal R, Tyagi P, Bansal N, Singla V, et al. Usefulness of transient elastography by FibroScan for the evaluation of liver fibrosis. *Indian J Gastroenterol* 2014;33:445-51.
- Castera L, Forns X, Alberti A. Non-invasive evaluation of liver fibrosis using transient elastography. *J Hepatol* 2008;48:835-47.
- Bota S, Sporea I, Peck-Radosavljevic M, Sirlin R, Tanaka H, Iijima H, et al. The influence of aminotransferase levels on liver stiffness assessed by Acoustic Radiation Force Impulse Elastography: a retrospective multicentre study. *Dig Liver Dis* 2013;45:762-8.
- Pavlov CS, Casazza G, Nikolova D, Tsochatzis E, Gluud C. Systematic review with meta-analysis: diagnostic accuracy of transient elastography for staging of fibrosis in people with alcoholic liver disease. *Aliment Pharmacol Ther* 2016;43:575-85.
- Sandrin L, Fourquet B, Hasquenoph JM, Yon S, Fournier C, Mal F, et al. Transient elastography: a new noninvasive method for assessment of hepatic fibrosis. *Ultrasound Med Biol* 2003;29:1705-13.
- Yoneda M, Mawatari H, Fujita K, Fujita K, Endo H, Iida H, et al. Noninvasive assessment of liver fibrosis by measurement of stiffness in patients with nonalcoholic fatty liver disease (NAFLD). *Dig Liver Dis* 2008;40:371-8.
- Myers RP, Pomier-Layrargues G, Kirsch R, Pollett A, Duarte-Rojo A, Wong D, et al. Feasibility and diagnostic performance of the FibroScan XL probe for liver stiffness measurement in overweight and obese patients. *Hepatology* 2012;55:199-208.
- Kim SU, Lee JH, Kim DY, Ahn SH, Jung KS, Choi EH, et al. Prediction of liver-related events using fibroscan in chronic hepatitis B patients showing advanced liver fibrosis. *PLoS one* 2012;7:e36676.
- Maimone S, Calvaruso V, Pleguezuelo M, Squadrito G, Amaddeo G, Jacobs M, et al. An evaluation of transient elastography in the discrimination of HBeAg-negative disease from inactive hepatitis B carriers. *J Viral Hepat* 2009;16:769-74.
- Huang R, Jiang N, Yang R, Geng X, Lin J, Xu G, et al. Fibroscan improves the diagnosis sensitivity of liver fibrosis in patients with chronic hepatitis B. *Exp Ther Med* 2016;11:1673-7.
- EASL-ALEH Clinical Practice Guidelines: Non-invasive tests for evaluation of liver disease severity and prognosis. *J Hepatol* 2015;63:237-64.