

The Uterine Adenosarcoma in a Young Woman Treated by TAH/BOS and Combined Adjuvant Therapy: A Case Report

Soodabeh Shahidsales¹, Marjaneh Farazestanian², Noorieh Sharifi-Sistani³, Sara Rasta⁴, Seyed Alireza Javadinia⁵

¹ Cancer Research Center, Mashhad University of Medical Sciences, Mashhad, Iran

² Department of Obstetrics and Gynecology, Faculty of Medicine, Mashhad University of Medical Sciences, Mashhad, Iran

³ Department of Pathology, Faculty of Medicine, Mashhad University of Medical Sciences, Mashhad, Iran

⁴ Student Research Committee, Mashhad University of Medical Sciences, Mashhad, Iran

⁵ Cellular and Molecular Research Center, Sabzevar University of Medical Sciences, Sabzevar, Iran

Received: 14 Nov. 2019; Accepted: 08 Feb. 2020

Abstract- We aimed to report a woman suffering from uterine adenosarcoma in the perimenopause period. The patient had undergone total abdominal hysterectomy (TAH) with bilateral salpingo-oophorectomy (BSO) and also received adjuvant chemotherapy and radiotherapy. Moreover, she was reported as disease-free with no evidence of recurrence or metastasis despite the existence of numerous risk factors such as deep myometrial invasion as well as sarcomatous overgrowth after one year of follow-up. The results obtained about this patient could highlight the role of adjuvant therapy in terms of managing treatments for patients suffering from MASO, especially in the presence of deep myometrial invasion and an advanced stage.

© 2020 Tehran University of Medical Sciences. All rights reserved.

Acta Med Iran 2020;58(3):138-141.

Keywords: Uterine adenosarcoma; Treatment; Adjuvant therapy

Introduction

Uterine adenosarcoma is recognized as a relatively rare malignancy in women, accounting for approximately 5% of uterine sarcomas and not as much of 1% of malignancies in this domain (1). This tumor is most frequently derived from the endometrium and is distinguished by its unique structure, which is typically comprised of the benign glandular epithelium (with or without atypical components) that can develop into malignant forms in combination with a mesenchymal component that is normally a low-grade sarcoma although there is the probability of being a high-grade one (2,3). In general, the prognosis of affected patients is good despite the fact that recurrence and survival rates are strongly influenced by risk factors such as sarcomatous overgrowth, lymphovascular space invasion, as well as a deep myometrial invasion (4,5).

At present, TAH with BSO is known as initial treatments of patients suffering from uterine adenosarcoma, which have been agreed upon by all physicians (4). Undeniably, there is a difference of opinion on other dimensions of such therapy for these

patients both in terms of surgical treatments (necessity of oophorectomy or lymphadenectomy (6,7) and adjuvant therapies (urgency for chemotherapy or radiotherapy (4).

In this case report, a young woman suffered from uterine adenosarcoma tracked after undergoing types III radical hysterectomy, and combined adjuvant therapy was introduced.

Case Report

A 24-year-old woman referred to the Women's Health Service Center due to abnormal bleeding between menstrual cycles was introduced. The patient had suffered from nodular goiter with hyperthyroidism five years ago; for that reason, she had been subjected to thyroidectomy in 2013 and had been subsequently treated with thyroid hormone replacement therapy via Levothyroxine. In terms of family history or other medical conditions, no particular problem was reported. Considering the laboratory examination of blood cell counts, they were found normal, and also, the serum levels of beta-human chorionic gonadotropin and

Corresponding Authors: S.A. Javadinia*, S. Rasta**

* Cellular and Molecular Research Center, Sabzevar University of Medical Sciences, Sabzevar, Iran

Tel: +98 5138426082, Fax: +98 51384286, E-mail address: javadiniaa941@mums.ac.ir

** Student Research Committee, Mashhad University of Medical Sciences, Mashhad, Iran

Tel: +98 5138426082, Fax: +98 51384286, E-mail address: RastaS951@mums.ac.ir

thyroid-stimulating hormone were reported equal to 0.6 mIU/ml And 0.5 milli-international units per liter, respectively. The results of other tests were also described as normal. Considering the refusal of systemic causes of menstrual disturbances and also that of pregnancy in the given patient, she received pelvic-abdominal ultrasound test, and consequently, a heterozygous mass of 45×12 mm on the endometrial site was reported. Other areas, such as ovaries, para-aortic lymph nodes, and liver, were found to be normal. To more accurately evaluate the nature and the location of the mass observed during the ultrasound test, computed tomography scan (CT scan) of the abdomen and the pelvis with and without injected contrast was provided; indicating the presence of a hypodense region of the uterus with an enlarged thickness of the endometrium (Figure 1). It should be noted that the results of the ultrasound test of other abdominal and pelvic regions were reported normal.

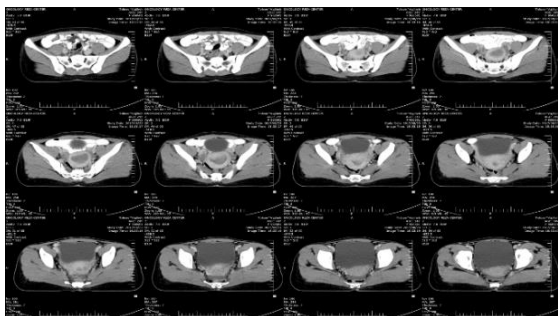


Figure 1. CT scan with and without IV contrast of the abdomen, and the pelvis with and without injected contrast was provided; indicating the presence of a hypodense region of the uterus with an enlarged thickness of the endometrium

Following the probable diagnosis of endometrial malignancies, the patient received diagnostic curettage to provide a report for the pathology of the biphasic Mullerian neoplasm. Then, the patient underwent TAH with BSO. In the postoperative pathology, a tumor lesion of 4×1.5×3 cm was observed that had affected more than 50% of myometrial. The microscopic findings of the lesion also revealed composed of dilated, cystically benign glands, and neoplastic stroma by overgrowth that was compatible with the adenosarcoma was invasive. To differentiate the tumor from other diagnostics, immunohistochemical staining was performed on the patient stained for CD10, ER, and PR, and the incidence rate of Ki67 was estimated by 40%. On the whole, the optical microscopic findings, as well as immunohistochemical ones, supported the pathological diagnosis of MASO (Figure 2).

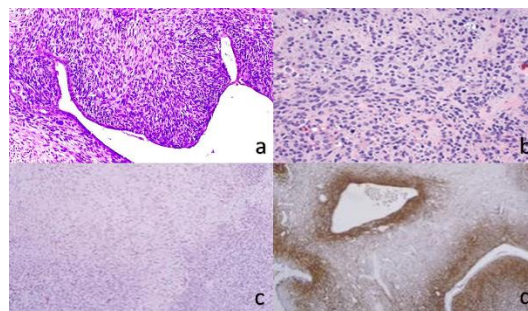


Figure 2. Microscopic findings of MASO. a. Microscopic view of uterine adenosarcoma, composed of dilated, cystically benign glands, and neoplastic stroma by overgrowth (H&Ex1000), b. The neoplastic stroma of adenosarcoma composed of spindle cell neoplastic lesion without glandular element (H&Ex400), c. Adenosarcoma with foci necrosis by shadow cell (H&Ex400), d. IHC study of adenosarcoma for CD10 marker by periglandular cell immunoreactivity (x400)

The patient was reviewed by the oncology genomics and tumor board, and considering the presence of numerous risk factors for recurrence and survival, such as the existence of sarcomatous overgrowth and deeply invasive tumor, she was advised on the onset of adjuvant chemotherapy with Ifosfamide plus Doxorubicin regimen and then repeated staging. In the absence of metastasis, chemotherapy followed by adjuvant radiotherapy was recommended. Therefore, three times of injectable chemotherapy in the form of Ifosfamide 1500 mg/m² along with Doxorubicin 20 mg/m² (both on days one and four) every three weeks plus bladder protection (Mensa) was prescribed for the patient. After three times of chemotherapy, the results of CT scan of the chest, the abdomen, and the pelvis with and without contrast injection showed no evidence of metastasis, so chemotherapy continued more than three times (totally six times). The main complications associated with chemotherapy were alopecia and nausea. Following the completion of the chemotherapy course, the patient underwent pelvic radiotherapy in a three-dimensional total dose of 50 g in five weeks. After a 12-month period from the time of diagnosis of the patient as disease-free, no evidence of recurrence or metastasis was reported.

Discussion

In this case report, a patient affected with uterine adenosarcoma in the perimenopause period was introduced. This individual had undergone TAH with BSO as well as adjuvant chemotherapy and radiotherapy, and she was also reported disease-free with no evidence of recurrence or metastasis despite the presence of several risk factors such as deep myometrial

The uterine adenosarcoma in a young woman

invasion and sarcomatous overgrowth based on a one-year follow-up.

The diagnosis of uterine adenosarcoma has been mainly reported at the age of 50 years and over, and the occurrence of this disease, especially the pathologic variant of MASO, has been very rare in patients in their perimenopause period (6,4,8). Like other uterine pathologies, the most common clinical manifestations of the given disease are menstrual disorders and abnormal vaginal bleeding highlighting the importance of considering prolonged abnormal bleeding after the rejection of pregnancy and hormonal causes via curettage and imaging (9). In the patient introduced in the present study, there were complaints of abnormal bleeding between menstrual cycles in which a voluminous heterogeneous mass was reported and approved through a CT scan after ruling out systemic causes of menstrual disturbances and also refused pregnancy following ultrasound test of the abdomen and the pelvis. It should be noted that such tumors can be in the form of pelvic masses, uterine polyps, or enlarged uterus (10).

Nowadays, TAH with BSO is standard treatments agreed upon by most physicians (4). However, there is strong disagreement on other therapeutic dimensions, such as the need to perform oophorectomy or lymphadenectomy (6,7) as well as the necessity for adjuvant chemotherapy or radiotherapy (4). There is also no consensus on adjuvant therapies. Some physicians also believe that such treatments in patients with high-risk manifestations such as advanced stage, deep myometrial invasion, presence of vascular invasion, sarcomatous overgrowth, as well as administration of adjuvant therapy are associated with survival benefit and reduced mortality caused by the disease (4). For the purpose of adjuvant chemotherapy, sarcoma-based diets usually contain Ifosfamide and Doxorubicin, whose effectiveness has been reported in some studies, although some other investigations have not confirmed their usefulness (11,12). In the domain of radiotherapy, small series have been presented, which mainly signify the role of this treatment in moderating local recurrences (4,8,13).

As mentioned; in the absence of some risk factors, patients with early-stage uterine adenosarcoma have a good prognosis, but if there are any of the existing factors, pathologic such as advanced stage accompanied by deep myometrial invasion, presence of vascular invasions, and sarcomatous overgrowth as well as the probability of recurrence is increased, and survival rate is obviously reduced (4). However, the

patient was diagnosed as disease-free one year after the definitive surgical treatment and adjuvant chemotherapy and radiotherapy despite the presence of a significant portion of these risk factors.

In the absence of some risk factors, patients with early-stage uterine adenosarcoma had a good prognosis, but if there were any of the existing factors, the pathologic path such as advanced stage accompanied by deep myometrial invasion, presence of vascular invasions, and sarcomatous overgrowth, as well as the probability of recurrence was increased, and survival was undoubtedly diminished. The results obtained from this patient highlighted the role of adjuvant therapies in treating patients affected with MASO, especially in the presence of deep myometrial invasion and advanced stage.

References

1. Friedlander ML, Covens A, Glasspool RM, Hilpert F, Kristensen G, Kwon S, et al. Gynecologic Cancer InterGroup (GCIg) consensus review for mullerian adenosarcoma of the female genital tract. *Int j gynecol cancer* 2014;24:S78-82.
2. D'Angelo E, Spagnoli LG, Prat J. Comparative clinicopathologic and immunohistochemical analysis of uterine sarcomas diagnosed using the World Health Organization classification system. *Hum pathol* 2009;40:1571-85.
3. Hensley ML. Uterine sarcomas: histology and its implications on therapy. *Am Soc Clin Oncol educ book* 2012:356-61.
4. Carroll A, Ramirez PT, Westin SN, Soliman PT, Munsell MF, Nick AM et al. Uterine adenosarcoma: an analysis on management, outcomes, and risk factors for recurrence. *Gynecol oncol* 2014;135:455-61.
5. Kaku T, Silverberg SG, Major FJ, Miller A, Fetter B, Brady MF. Adenosarcoma of the uterus: a Gynecologic Oncology Group clinicopathologic study of 31 cases. *International journal of gynecological pathology. Int J Gynecol Pathol* 1992;11:75-88.
6. Arend R, Bagaria M, Lewin SN, Sun X, Deutsch I, Burke WM, et al. Long-term outcome and natural history of uterine adenosarcomas. *Gynecol Oncol* 2010;119:305-8.
7. Goh C, Lin XH, Chin PS, Lim YK. Uterine preservation in a young patient with adenosarcoma of the uterus - Case report and review of literature. *Gynecol oncol rep* 2018;25:27-9.
8. Krivak TC, Seidman JD, McBroom JW, MacKoul PJ, Aye LM, Rose GS. Uterine adenosarcoma with sarcomatous overgrowth versus uterine carcinosarcoma:

- comparison of treatment and survival. *Gynecol Oncol*. 2001;83:89-94.
9. Farhat MH, Hobeika EM, Moumneh G, Nassar AH. Uterine mullerian adenosarcoma with sarcomatous overgrowth fatal recurrence within two weeks of diagnosis: a case report. *J Med Case Rep* 2007;1:103.
 10. Verschraegen CF, Vasuratna A, Edwards C, Freedman R, Kudelka AP, Tornos C, et al. Clinicopathologic analysis of mullerian adenosarcoma: the M.D. Anderson Cancer Center experience. *Oncol rep* 1998;5:939-44.
 11. Lee SJ, Bae JH, Kim DC, Park JS, Namkoong SE. Oral progesterone treatment in a young woman with mullerian adenosarcoma whose ovary was preserved: a case report. *Int j gynecol cancer* 2010;20:1222-4.
 12. Zaloudek CJ, Norris HJ. Adenofibroma and adenosarcoma of the uterus: a clinicopathologic study of 35 cases. *Cancer* 1981;48:354-66.
 13. Tanner EJ, Toussaint T, Leitao MM, Jr., Hensley ML, Soslow RA, Gardner GJ et al. Management of uterine adenosarcomas with and without sarcomatous overgrowth. *Gynecol Oncol* 2013;129:140-4.