

Renal Oncocytoma: A Large Tumor, Report of a Case and Review of Literature

Mazaher Ramezani^{1,2}, Kimia Karami^{1,2}, Kaivan Mohammadi^{1,2}, Farideh Baharzadeh^{1,2}

¹ Molecular Pathology Research Center, Imam Reza Hospital, Kermanshah University of Medical Sciences, Kermanshah, Iran

² Clinical Research Development Center, Imam Reza Hospital, Kermanshah University of Medical Sciences, Kermanshah, Iran

Received: 12 Apr. 2022; Accepted: 18 Dec. 2022

Abstract- Oncocytoma is a common benign kidney tumor. The size is often less than 5 cm. Oncocytomas may be misdiagnosed in clinic, radiology and histopathology for renal cell carcinoma. Different panels of immunohistochemistry (IHC) are suggested in the renal tumors with eosinophilic granular cytoplasm including oncocytoma, chromophobe and clear renal cell carcinoma. Here we report a large oncocytoma in a 64-year-old lady, that the mimickers ruled out by IHC.

© 2023 Tehran University of Medical Sciences. All rights reserved.

Acta Med Iran 2023;61(1):61-63.

Keywords: Renal oncocytoma; Case report; Large tumor

Introduction

Oncocytoma is considered as the most common benign kidney tumor (1) or the second most common after angiomyolipoma (2). It consists of 5-7% of renal tumors (3). It may presents as palpable abdominal mass (4), abdominal and epigastric pain (5), however mainly incidentally in imaging (6). More rare presentations include recurrent urinary tract infection and flank pain (2) or even visual disturbance for paraneoplastic syndrome (7). It presents usually in the seventh decade of life, but a wide range of 10-86 years are in the literature (2). The size is often less than 5 cm (8), but many large tumors are on record (1, 4, 5, 6, 8). Oncocytomas may be misdiagnosed in clinic and radiology for renal cell carcinoma (1,6). Different panels of immunohistochemistry (IHC) are suggested in the renal tumors with eosinophilic granular cytoplasm (9,10). CD117 has been used with controversial results (9-11). Here we report a large tumor with pathologic diagnosis of oncocytoma.

Case Report

A 64-year-old woman on 17th September 2017 referred for ultrasound evaluation with urinary symptoms and flank pain. A large mass (10 cm) noted in right kidney and finally the patient was candidate for

nephrectomy. No weight loss, anorexia, hematuria, bone pain or dyspnea was noticed in the history. In past medical history, the patient had hypothyroidism and hyperlipidemia under treatment. Surgical history was tubal ligation 18 years ago. Medication history was levothyroxine, gemfibrozil, livergol and Vitamin E. Vital signs were stable and physical examination was unremarkable. Computed tomography (CT) scan showed solid large mass measured 63x95 mm in right lower pole of kidney in parenchyma and sinus with extension to perirenal fat. Radiology report suggested hypernephroma. Lymphadenopathy on right renal hilum was noticed (17 mm). Lab data was Hemoglobin, 12.8 g/dl and 8.7 g/dl (before and after surgery respectively, Reference range: 12.0-15.5 g/dl). Urea was 59 mg/dl (Reference range: 5-20 mg/dl) and creatinine, 1.5 mg/dl (Reference range: 0.5-1.0 mg/dl). Other lab data including calcium, alkaline phosphatase, serum K and Na were within normal limits. Right radical nephrectomy was done on 18th September with clinical diagnosis of renal cell carcinoma. Specimen was sent to pathologist and consisted of kidney measured 13x8x7 cm. Ureter measured 5x0.5 cm. Cut sections revealed a brown mass measured 10 cm in diameter (Figure 1).

Pathologist reported: "compatible with oncocytoma limited to renal capsule (Figure 2). Tumor greatest diameter is 10 cm. Vascular and ureteral margins are free of tumor. Focal nuclear pleomorphism is present".

Corresponding Author: M. Ramezani

Molecular Pathology Research Center, Imam Reza Hospital, Kermanshah University of Medical Sciences, Kermanshah, Iran
Tel: 98 8334282906, E-mail address: mazaher_ramezani@yahoo.com

Copyright © 2023 Tehran University of Medical Sciences. Published by Tehran University of Medical Sciences

This work is licensed under a Creative Commons Attribution-NonCommercial 4.0 International license (<https://creativecommons.org/licenses/by-nc/4.0/>). Non-commercial uses of the work are permitted, provided the original work is properly cited

Large renal oncocytoma

Immunohistochemistry (IHC) results showed positivity for Cytokeratin (CK)8 (Figure 3) and Cluster of designation (CD)117 and negativity for Vimentin, CD10, CK7 and CK20. The patient discharged on 23rd September with good condition and stable vital signs. Written informed consent was obtained from the patient. No further follow up was available for the pathologist.



Figure 1. Gross appearance of tumor in the middle portion of kidney

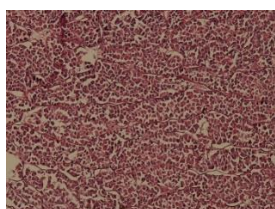


Figure 2. Microscopic appearance of oncocytoma. Nests composed of cells with eosinophilic granular cytoplasm. Hematoxylin-Eosin stain X 100 Magnification

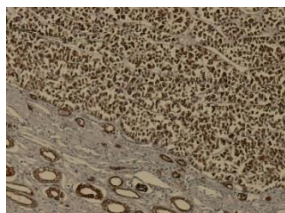


Figure 3. Immunohistochemistry for CK8. Positive staining X100 Manification

Discussion

We reported a 64-year-old lady with 10 cm renal mass with perirenal fat involvement and lymphadenopathy. She was hyperlipidemic and hypothyroid. About 12% of cases show evidence of vascular and/or perinephric fat involvement (12). Variable associations with varicocele (6), schwannoma (13), bladder tumor (8) and hyperthyroidism (14) are on record. These associations may be by chance and sometimes is the leading cause of misdiagnosis (13). Some cases are even misdiagnosed as metastatic renal cell carcinoma (1,13). Tyler reported a 63 year man with oncocytoma and retroperitoneal schwannoma, that misinterpreted as metastatic renal cell carcinoma (13). Evidence of bone and liver metastasis in the case of Sumi Dey (1) culminated in radical nephrectomy in the patient and made the author to recommend biopsy before radical surgery. In the present case IHC showed CK8 and CD117 positivity, but Vimentin, CD10, CK7, and CK20 negativity. Geramizadeh suggested the panel of Vimentin, CK7, CD10, RCC marker and Hale's colloidal iron for differentiation of oncocytoma, chromophobe and conventional renal cell carcinoma but not CK8/18, CK19, CK20 and EMA (9). Wei Zhao suggested the panel of DOG1, cyclin D1, CK7, CD117 and Vimentin but not CK8/18, CK19, CD10, Beta-catenin, and E-cadherin. Table 1 shows the summary of the findings of Geramizadeh (9) and Wei Zhao (10). CK8 was positive in chromophobe renal cell carcinoma (ChRCC), clear cell renal cell carcinoma (CRCC) and oncocytoma in 93%, 70% and 87.5% of cases respectively and not useful for differentiation (9). Similar to the above-mentioned reports of CD117 positivity in oncocytoma, our case was positive for CD117. However, Qianru Guo (11) described low grade oncocytic tumors, all of them were CD117 negative while CK7 positive. Our case was CD117 positive and CK7 negative. Oncocytomas may be considered a heterogenous group, regarding CD117 staining results.

Table 1. Immunohistochemistry panel for renal tumors of eosinophilic cytoplasm.

Tumor/Marker	DOG1	Cyclin D1	CK7	CD117	Vimentin	CD10	RCC marker
ChRCC	+	-	+	+	-	-	-
CRCC	-	-	-	-	+	+	+
Oncocytoma	+	+	-	+	-	-	-

Large tumors of the kidney may be benign. Oncocytoma, as a benign tumor has differential

diagnosis with malignant renal tumors in histopathology. Pathologist should be familiar with this entity and

choose appropriate panel of IHC for definite diagnosis.

Acknowledgments

The authors would like to thank the Clinical Research Development Center of Imam Reza Hospital for Consulting Services.

References

1. Dey S, Noyes SL, Uddin G, Lane BR. Palpable Abdominal Mass is a Renal Oncocytoma: Not All Large Renal Masses are Malignant. *Case Rep Urol* 2019;2019:6016870.
2. Abualjadayel MH, Safdar OY, Banjari MA, El Desoky S, Mokhtar GA, Azhar RA. A Rare Benign Tumor in a 14-Year-Old Girl. *Case Rep Nephrol* 2018;2018:1548283.
3. Balaji AR, Prakash JVS, Darlington D. Cystic renal oncocytoma mimicking renal cell carcinoma. *Urol Ann* 2019;11:98-101.
4. Sussman RD, Kowalczyk KJ. Giant renal oncocytoma with classic stellate scar. *BMJ Case Rep* 2017;2017:bcr2016218944.
5. Kolníková G, Marinová P, Gál V, Mečiarová I, Mišanko V, Rampalová J, et al. Renal oncocytoma with invasive histopathologic features-case report. *Klin Onkol* 2014;27:138-42.
6. Shakarchi J, Wharton I, Youssef A, Anderson P. Giant renal oncocytoma. *Radiol Case Rep* 2015;4:307.
7. Cheng JL, Beebe JD, Nepple KG, Zakharia Y, Mullins RF, Flamme-Wiese MJ, et al. Autoimmune retinopathy and optic neuropathy associated with enolase-positive renal oncocytoma. *Am J Ophthalmol Case Rep* 2018;12:55-60.
8. Badmus TA, Adesunkanmi AR, Agbakwuru CA, Salako AA, Uhumwagho O, Eziyi AK. Giant renal oncocytoma masquerading as infiltrating renal cell carcinoma: case report and literature review. *Cent Afr J Med* 2006;52:16-9.
9. Geramizadeh B, Ravanshad M, Rahsaz M. Useful markers for differential diagnosis of oncocytoma, chromophobe renal cell carcinoma and conventional renal cell carcinoma. *Indian J Pathol Microbiol* 2008;51:167-71.
10. Zhao W, Tian B, Wu C, Peng Y, Wang H, Gu WL, et al. DOG1, cyclin D1, CK7, CD117 and vimentin are useful immunohistochemical markers in distinguishing chromophobe renal cell carcinoma from clear cell renal cell carcinoma and renal oncocytoma. *Pathol Res Pract* 2015;211:303-7.
11. Guo Q, Liu N, Wang F, Guo Y, Yang B, Cao Z, et al. Characterization of a distinct low-grade oncocytic renal tumor (CD117-negative and cytokeratin 7-positive) based on a tertiary oncology center experience: the new evidence from China. *Virchows Arch* 2021;478:449-58.
12. Omiyale A, Carton J. Renal oncocytoma with vascular and perinephric fat invasion. *Ther Adv Urol* 2019;11:175628721988485.
13. Maiers TJ, Wang DC, Houjaij AH, Darwish OM. Renal Oncocytoma and Retroperitoneal Ancient Schwannoma: A Benign Mimic of Metastatic Renal Cell Carcinoma. *Case Rep Urol* 2019;2019:2561289.
14. Knechtle B, Neuweiler J, Berchtold D. Fallbeschreibung: Renales Onkozytom und Basedow-Hyperthyreose [Case report: renal oncocytoma and Basedow hyperthyroidism]. *Praxis (Bern 1994)* 1994;83:1256-60.