

Point of Care Usg in Icu– Three in One

Sonu Sama*, Vijay Adabala, Sagarika Panda

Department of Anesthesiology, All India Institute of Medical Sciences Rishikesh, Rishikesh, India.

ARTICLE INFO

Article history:

Received 03 April 2020

Revised 24 April 2020

Accepted 09 May 2020

Keywords:

Ultrasound;

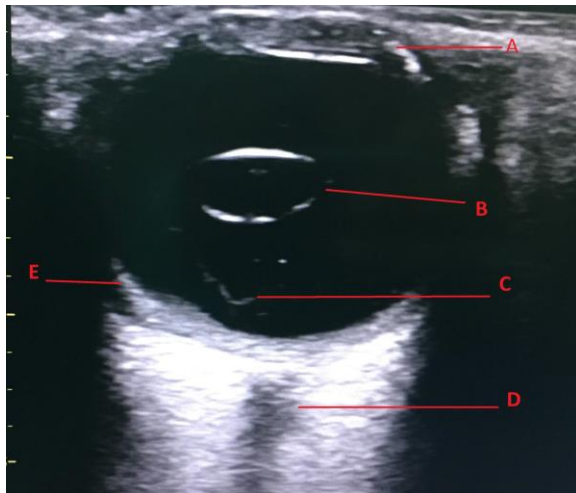
Eye;

ICU

© 2020 Tehran University of Medical Sciences. All rights reserved.

50 year 50 year old male case of road traffic accident with subarachnoid hemorrhage, ileal perforation and multiple rib fractures on right side was admitted in ICU for further management. Examination revealed anisocoria with dilated pupil on right side. Ultrasonography (USG) of right eye showed dislocation of the lens, vitreous hemorrhage and retinal detachment (Figure1) which made the further management of the case quicker.

Figure 1- USG of Eye B Mode



A- Cornea

B- Dislocated Lens

C- Vitreous Hemorrhage

D- Optic Nerve

E- Retinal Detachment

USG of eye is done using linear probe on B scan mode. The most common indication of ultrasound eye in ICU is to measure optic nerve sheath diameter (ONSD) to rule out raised ICT [1]. Careful evaluation can reveal a lot of information and looking beyond ONSD is the need of the hour. If not diagnosed at an appropriate time it could lead to permanent vision loss. Point-of-care ultrasonography demonstrated overall sensitivity of 96.9% and specificity of 88.1% for the diagnosis of retinal detachment, 81.9% sensitivity and 82.3% specificity for vitreous hemorrhage [2]. Although it's a well-known fact to utilize ultrasound in eye examination in ED combination of these three time bound pathologies is rarely reported in a single patient. On behalf of all authors, the corresponding author states that there is no conflict of interest.

References

- [1] Blaivas M, Theodoro D, Sierzenski PR. Elevated intracranial pressure detected by bedside emergency ultrasonography of the optic nerve sheath. *Acad Emerg Med.* 2003; 10(4):376-81.
- [2] Lahham S, Shniter I, Thompson M, Le D, Chadha T, Mailhot T, et al. Point-of-care ultrasonography in the diagnosis of retinal detachment, vitreous hemorrhage, and vitreous detachment in the emergency department. *JAMA Netw Open.* 2019; 2(4):e192162.

The authors declare no conflicts of interest.

*Corresponding author.

E-mail address: sonusama9287@gmail.com

© 2020 Tehran University of Medical Sciences. All rights reserved.