



## Meningeal Hemorrhage Secondary to an Electrization Accident about an Observation in a Resuscitation Department in Abidjan (RCI)

Nkan Michael Paterne Mobio<sup>1\*</sup>, Abhe Chacke Maria<sup>1</sup>, Coulibaly Theodore Klinna<sup>1</sup>, Ouattara Abdoulaye<sup>1</sup>, Netro Djohui Edwige<sup>2</sup>, Nguessan Yapi Francis<sup>2</sup>, Tetchi Yavo Denis<sup>1</sup>

<sup>1</sup>Anesthesia resuscitation, Universite Félix Houphouet Boigny (CHU of Cocody), Abidjan, Ivory Coast.

<sup>2</sup>Anesthesia resuscitation, Universite Félix Houphouet Boigny (CHU of Angre), Abidjan, Ivory Coast.

### ARTICLE INFO

#### Article history:

Received 19 August 2019

Revised 11 September 2019

Accepted 26 September 2019

#### Keywords:

Electrification;

Haemorrhage;

Meningeal;

Resuscitation;

### ABSTRACT

During electrical accidents, various mechanisms are observed: electric flash, electric arc, lightning and true electrification. Whatever the mechanism, various types of lesions can be observed such as subarachnoid hemorrhages. Exposure to a high voltage current, the appearance of initial consciousness disorder, the existence of skin burn lesions testifying to the passage of current through the cephalic end homolateral to the hemorrhage, the existence of hemorrhage meningeal at d0, the real existence of this complication in victims of lightning strikes (which is an electric shock) and the existence of a similar case in the literature make electric accidents, an etiology of hemorrhage meningeal.

© 2020 Tehran University of Medical Sciences. All rights reserved.

Electrization corresponds to all the physiological and physiopathological manifestations due to the passage of electric current through the human body, whereas the more commonly used term of electrocution generally corresponds to the death of the victim, most often on the premises of the victim's. accident [1-3]. Cerebro-meningeal haemorrhages secondary to a high-voltage electric current electrization accident are very rarely reported in the literature [4-5]. We report a case of subarachnoid hemorrhage secondary to electrification in a 34-year-old patient with no pathological antecedents, building electrician, while connecting a house to the electricity grid. This observation confirms the etiological hypothesis formulated by Chaidra and M Buguenne according to which AE by contact with a high-voltage electric current carrying cable is considered as an etiology of cerebral meningeal hemorrhage [4-5] and brings a particularity as to the time of occurrence of meningeal hemorrhage.

### Case Report

We report the case of Mr TB aged 34 years, weighing 85 kg, measuring 1.87 m without pathological antecedents, building electrician, who was the victim of an electrification accident while connecting a house to the electricity grid.

The patient is said to have had an obsessive-compulsive disorder, headache and jet vomiting. The patient would have been taken immediately by his parents to the center of the great burns of the CHU of Cocody who before the disorder of the conscience sent it to the service of resuscitation for a better management.

The clinical examination at admission revealed an obtundation with a Glasgow score of 13, with no sign of localization, associated with severe burn and hypovolemic shock. The total burned body surface was estimated at 38%, associating deep lesions of degree IIb and III and sitting at the level of the right and left forearms, of the posterior aspect of the thorax (left scapula), of the head (at the occipital level).

The authors declare no conflicts of interest.

\*Corresponding author.

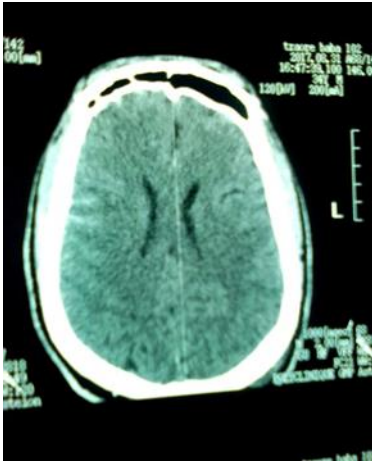
E-mail address: [mobiomichael1982@gmail.com](mailto:mobiomichael1982@gmail.com)

© 2020 Tehran University of Medical Sciences. All rights reserved.

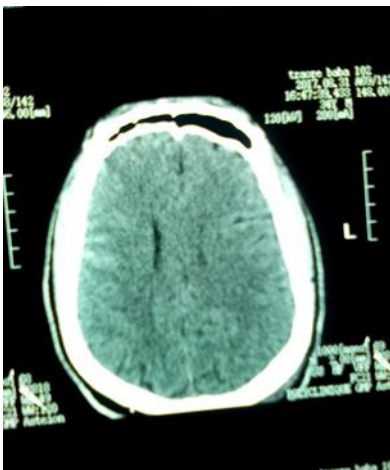
The biology revealed hyperleukocytosis (GB: 17000.10 3 PNN predominance 83%) and normochromic normochromic anemia (Hb: 9.77g / dl), hyperkalemia (5.96 mmol / l), liver cytolysis (ASAT: 120 IU / L and ALT: 145 IU / L) and impaired renal function (uremia: 1 g / L and serum creatinine: 39.3 mg / L). The ECG has noted repolarization disorders. The cranoencephalic CT scan, performed on the day of admission, showed right temporoparietal meningeal hemorrhage and diffuse cerebral edema. There were no other associated lesions. (Figure 1).

**Figure 1- Brain CT.**

**A- Temporary parietal meningeal hemorrhage**



**B- Diffuse cerebral edema**



Initial treatment consisted of volume resuscitation based on the Parkland formula. The patient received an electrolytic hydration of 6 l of crystalloids during the first 8 hours and 6l for the remaining 16 hours. It was instituted by an antibiotic treatment based ceftriaxone 2g in IVD per day, a serotonin 1500 IU subcutaneous immunotherapy, an analgesic plateau 3 and finally a prevention of thromboembolic disease by enoxaparin 4000 IU subcutaneously.

Surgical treatment, performed at hospitalization, consisted of stripping under general anesthesia terminated by an occlusive dressing after application of dakin and flammazine ointment. The patient received a blood transfusion isogroup isoperated intraoperatively with erythrocyte concentrate (411 cc) in the presence of heavy bleeding.

The evolution on day 10 was marked by the installation of severe sepsis in the wake of the aggravation of coma-type consciousness disorder with a Glasgow score of 6, the installation of an infectious syndrome and instability. hemodynamic hypotension type. An infectious report was made. An adaptation of antibiotherapy to the antibiogram was made. The patient was intubated, ventilator-assisted, and vasoactive amines started. An indication of amputation of both hands was put by the surgeons before the appearance of necrosis lesions but the precariousness of the hemodynamic state and the refusal of the parents did not make it possible. The patient died of hospitalization J13 in a context of septic shock.

### Discussion

According to the literature, the most thorough clinical studies of the neurological manifestations of AEs are made from post-lightning accidents [6,4,7]. However, two observations have reported the occurrence of cerebral haemorrhage following electrification by a high voltage electric current [4-5]. For these two authors, AE by contact with a high-voltage electrical current carrying cable should be considered as a possible etiology of cerebro-meningeal hemorrhage. The etiological circumstances found in these two observations are identical to ours; these are: (a) exposure to a high-voltage current, (b) brief initial loss of consciousness, (c) the existence of skin burn injuries indicative of current flow through the ipsilateral cephalic extremity. cerebral haemorrhage, (d) the real existence of this complication in the victims of lightning, which is an AE [4]. The difference between our observation and the two preceding ones is at the time of occurrence of meningeal haemorrhage, hence the peculiarity of our observation. In our case, meningeal haemorrhage was observed in the hours following AE in Chaibdraa, meningeal haemorrhage occurred three days after AE and in the observation of Bugueme M [4-5] it was highlighted two months after the AE. This difference in time to onset or observation of meningeal hemorrhage does not jeopardize the etiology of the latter because according to Chuang, hemorrhagic arterial complications occur up to six weeks after the initial accident [8]. The vessels and nerves offer less resistance and are therefore the seat of a stronger intensity, from which it is recognized that the path of electrification is preferentially vasculo-nervous. Electricity has a specific role on the vessels, especially on

the arteries causing thromboses, a weakening of the wall of small arteries can break causing hemorrhages.

Cherington classifies secondary neurological disorders into four major groups according to the date of onset and mode of evolution [9-10].

Group 1 is made of immediate and transient lesions and consists of brief unconsciousness, confusion, headache, amnesia, paresthesia and asthenia. The predominant paralysis in the lower limbs (Charcot keratoparalysis) is accompanied by pallor, severe vasoconstriction with decreased pulse and arterial hypertension. Only obtundation and headache were noted in our patient. Cherington points out that brief loss of consciousness is the most frequently found sign [11]. This brief loss of consciousness was observed in Chaibdraa and M Buguenne [4-5]. In our observation, the patient presented a disorder of consciousness from the outset without a notion of recovery of consciousness. Group 2 includes immediate, prolonged and permanent lesions and defines cerebral, medullary and peripheral lesions. In the brain, cardiac post-cardiac encephalopathy, areas of infarction, cerebral edema, hemorrhage, cerebellar atrophy, hematomas; myelopathy with demyelination and a cord lesion are noted at the medullary level; peripheral deficits are caused by destruction of Schwann cells (axonal fragmentation), nerve compression syndrome (vascular obliteration and perineuronal fibrosis). In our patient, the lesions of this group that have been objectified are diffuse cerebral edema and right temporoparietal meningeal hemorrhage. This haemorrhage occurs during the first three days to six weeks following the initial accident [9, 4, 8] and remains permanent for several days. Group 3 is composed of delayed and progressive lesions and concerns long-term manifestations whose pathophysiological mechanisms are unknown. They can occur several months after the initial accident and are progressive: peripheral neuropathy, paresthesia, paresis, optic atrophy, cerebellar dysfunction, epilepsy, transverse myelitis, paraplegia, depression and memory and concentration problems [9,12]. The death during hospitalization of our patient did not allow us to detect this group of lesions. Group 4 consists of associated neurological lesions. These are the pathologies associated with the associated traumas and can be summed up in head trauma and medullary section. In our patient, none of these pathologies had been observed, but he had severe burns in both upper limbs, in the back and in the head. With regard to evolution, the morbidity caused by AEs is considerable with sequelae, in particular neurological and psychological, which can be very disabling [3]. In the observations of Chaibdraa and M Buguenne, patients with AE had a good clinical recovery without sequelae and the paraclinical control examinations were normal, but in our case, our patient died in a septic shock J 13 of hospitalization. The precariousness of the patients, the lack of social coverage, the unavailability of antibiotics

and the refusal of amputation of the necrotic upper limbs led to a delay of care which favored the installation of a severe sepsis then d septic shock leading to the death of our patient.

## Conclusion

Cerebral hemorrhages are central neurological manifestations well documented in post-lightning but whose physiopathological mechanism, according to the literature, is sometimes difficult to resolve: accident of true electrization or consequence of a cranial trauma often associated. Our literature search showed two similar observations of cerebro-meningeal hemorrhage following an electrocution accident by a high-voltage industrial current. In addition to confirming the hypothesis that AE is an etiology of cerebro-meningeal hemorrhage, our observation notes the precocity of its occurrence, contrary to previous observations.

## References

- [1] Jowdar S, Kismoune H, Boudjemia F, Bacha D. Electric burns - retrospective and analytical study on 588 cases over a decade 1984-1993. *Ann Burns Fire Disasters*. 1997; 10 (1): 20-7.
- [2] Berthin-Maghit M., Bouchard C., Gueugniaud PY, Petit P. Neurological deficit during the resuscitation of the burn victim: about three cases evoking a centropontic myelinolysis. *Burns, News from the SFETB*. 1996: 78-82.
- [3] Gueugniaud PY, Vaudelin G. Berlin - Maghit M, Small P. Accident d'électrisation. *Conf. d'Actu. SFAR*; 1997. p. 479-97.
- [4] Chaibdraa A, Medjellakh MS, Saouli A, Bentakouk MC. Accident d'électrisation et hémorragie cérébro-méningée: A propos d'une observation. *Ann Burns Fire Disasters*. 2008; 21(3): 133-7.
- [5] Bugeme M, Mukuku O. Manifestations neuropsychiatriques révélant une hémorragie cérébro-méningée causée par un accident d'électrisation: à propos d'une observation et revue de la littérature. *Pan Afr Med J*. 2014; 18: 201.
- [6] Remensnyder J.P. Acute electrical injuries. In: Martyn J.A.J., editor. *Acute management of the burned patient*. Philadelphia: W.B. Saunders; 1990. p. 66-86.
- [7] Mradmi W, Fassi-Fihri J, Mehaji G, Ezzoubi Mr, Diouri Mr, Bahechar N, et al. Brûlure par foudre: A propos d'une observation. *Ann Burns and Fire Disasters*. 2005; 18(3):127-29.
- [8] Chuang SS, Yu CC. Delayed obturation artery rupture: A complication of high-voltage electrical injury. *Burns*. 2003; 29(4):395-398.
- [9] Chaibdraa A, Medjellekh MS, Bentakouk MC. Electrisation – Electrocution. *Ann Burns Fire Disasters*. 2009; 22(1):22-32.
- [10] Cherington M. Neurologic manifestations of

- lightning strikes. *Neurology*. 2003; 60(2):182–5.
- [11] Cherington M. Central nervous system complications of lightning and electrical injuries. *Sem Neurol*. 1995; 15(3):233–240.
- [12] Bozkurt M, Deveci M, Sengezer M. Permanent paraplegia in an electrical burn patient following spinal anaesthesia (case report and review) *Ann. Burns and Fire Disasters*. 2001; 14:94-5.