

# Challenging Anesthetic Management in Ovarian Tumor Surgery with Underlying COPD and Cor Pulmonale: A Multisystem Consideration

Jayant Bhatia, Reshma Salim\*, Anushka Sharma

Department of Anaesthesiology, DR D Y Patil Medical College Hospital and Research Center, Dr D Y Patil Vidyapeeth, Pimpri, Pune, Maharashtra, India.

## ARTICLE INFO

### Article history:

Received 14 May 2025

Revised 04 June 2025

Accepted 18 June 2025

Ovarian mucinous cystadenomas, especially those of massive size, present considerable anesthetic challenges. These tumors can compress the diaphragm, reduce lung compliance, and shift intravascular volume, complicating both ventilation and hemodynamics during surgery [1]. Careful preoperative planning, intraoperative vigilance, and postoperative monitoring are essential to avoid morbidity and mortality. The importance of tailored ventilation and positioning strategies to address compromised respiratory physiology and altered venous return should be tackled with due vigilance [2].

This case explores the anesthetic management of a 42-year-old female patient weighing 68 kg, scheduled for the elective excision of a large ovarian mucinous cystadenoma diagnosed after a routine abdominal ultrasound. The cyst was approximately 30 x 20 cm in size (Figure 1-3) and had been gradually increasing in size over the years.

The patient presented with breathlessness (METs < 4) and a chronic cough with purulent sputum, suggestive of chronic obstructive pulmonary disease (COPD) for the past 2 years. Further workup confirmed a diagnosis of COPD; spirometry revealed significant airflow obstruction with no reversibility, consistent with a chronic and fixed obstructive pattern. A recent transthoracic echocardiogram showed EF=60%, right

ventricular hypertrophy, and moderate PAH with mild tricuspid regurgitation, confirming cor pulmonale. These findings added complexity to the anesthetic management due to the risk of right heart decompensation and the need for tailored ventilation.

Her past surgical history included an uncomplicated laparoscopic cholecystectomy under general anesthesia 10 years back, and preoperative laboratory investigations revealed polycythemia with an HCT of 54%. A wide QRS complex was identified on her ECG (QRS > 160 ms) (Figure 4), raising concern for potential arrhythmias that could complicate intraoperative management. Her preoperative vitals included heart rate—82 bpm, blood pressure—134/86 mmHg, and saturation—100% at room air.

Given the patient's respiratory and cardiovascular status, the patient was nebulized with salbutamol and budesonide inj. Hydrocortisone 100 mg was given night and morning of surgery, and a lung-protective ventilation strategy was employed.

During general anesthesia, PEEP was maintained at 5 cmH<sub>2</sub>O (Figure 5), to optimize oxygenation while minimizing the risk of barotrauma and right ventricular afterload increase. Tidal volume was limited to 4-5 mL/kg, and respiratory rate was adjusted to maintain normocapnia. These measures were crucial in preventing hyperinflation, dynamic air trapping, and further

The authors declare no conflicts of interest.

\*Corresponding author.

E-mail address: [reshmasalim63@gmail.com](mailto:reshmasalim63@gmail.com)

DOI: [10.18502/aacc.v12i1.20552](https://doi.org/10.18502/aacc.v12i1.20552)

Copyright © 2026 Tehran University of Medical Sciences. Published by Tehran University of Medical Sciences.



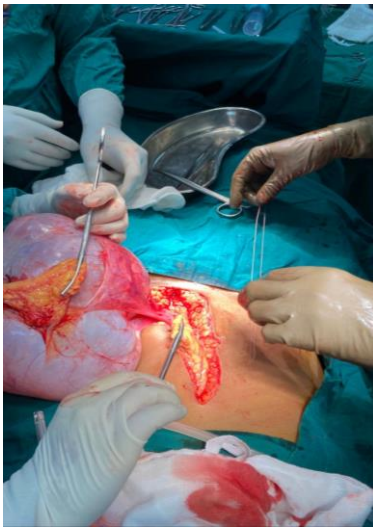This work is licensed under a Creative Commons Attribution-NonCommercial 4.0 International license (<https://creativecommons.org/licenses/by-nc/4.0/>). Noncommercial uses of the work are permitted, provided the original work is properly cited.

compromise of right ventricular function. General anesthesia was induced with Inj. Midazolam (0.02 mg/kg), Inj. Propofol (2 mg/kg), Inj. Fentanyl (2 mcg/kg), and Inj. Vecuronium (0.1 mg/kg). Inj. Glycopyrrolate was avoided, and vitals were closely monitored to prevent tachycardia, hypotension, and arrhythmic changes during induction.

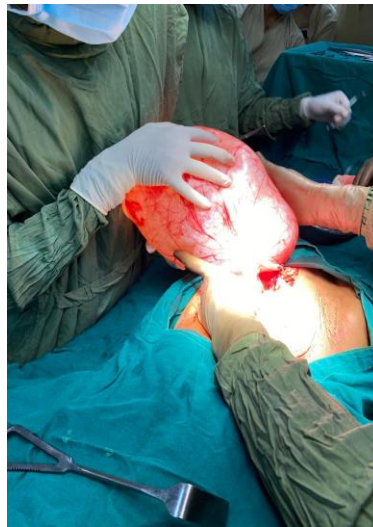Following intubation with a 7.0 mm cuffed endotracheal tube, controlled mechanical ventilation was initiated. Intraoperatively, an episode of desaturation ( $\text{SpO}_2$  – 76%) occurred, likely due to diaphragmatic compression and baseline reduced pulmonary reserve. After ruling out airway obstruction and equipment failure, PEEP was briefly increased to 8  $\text{cmH}_2\text{O}$ ,  $\text{FiO}_2$  70%, and intermittent manual ventilation was initiated,

which improved oxygenation. Hemodynamic stability was maintained throughout the case. However, a transient drop in blood pressure (MAP 59 mmHg) was promptly corrected with a saline bolus and phenylephrine 100 mcg boluses. Intraoperative management of the patient's cor pulmonale included infusion of milrinone @ 0.5 mcg/kg/min, careful fluid titration to avoid right heart overload, and continued vigilance for arrhythmias. Magnesium sulfate at 30 mg/kg was administered intraoperatively to stabilize and reduce arrhythmic risk.

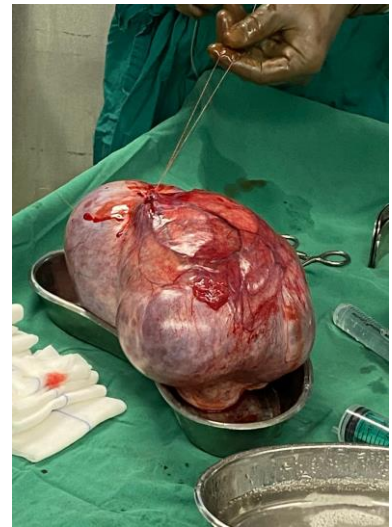The patient was successfully reversed with Inj. Suggamadex 4 mg/kg and extubated in the operating room with stable respiratory and cardiovascular parameters.



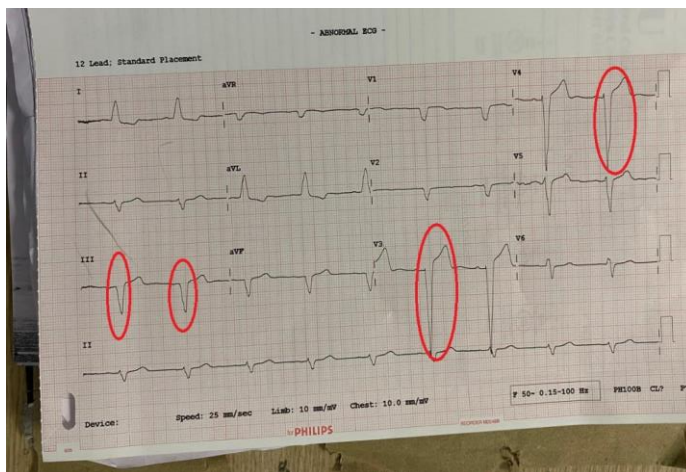
**Figure 1-** ovarian mucinous cyst



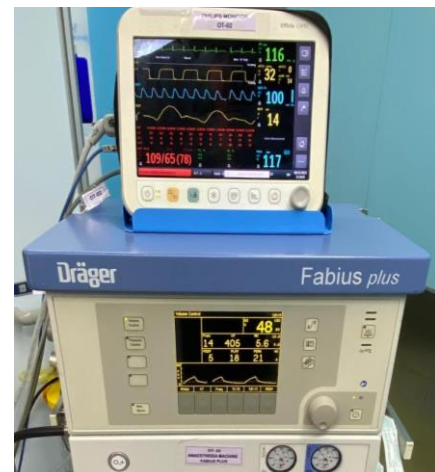**Figure 2-** removal of cyst



**Figure 3-** cyst of approximately 30 x 20 cm



**Figure 4-** A wide QRS complex in ECG (QRS > 160 ms)



**Figure 5-** ventilator settings

Postoperative monitoring focused on early detection of complications such as pulmonary edema,

hypoventilation, or right heart failure. She remained hemodynamically stable in recovery and received 2

L/min supplemental oxygen via nasal cannula, maintaining an SpO<sub>2</sub> of 92-94% for the first 12 hours due to underlying pulmonary pathology.

The anesthetic management of patients with coexisting COPD and cor pulmonale undergoing resection of large ovarian tumors necessitates a highly tailored approach [3-4]. In this case, proactive preoperative identification of pulmonary hypertension and right ventricular strain guided intraoperative strategies that preserved cardiopulmonary stability. Lung-protective ventilation, avoidance of agents that exacerbate pulmonary vascular resistance, and vigilant hemodynamic monitoring were key to the successful outcome. This case further emphasizes the value of a multidisciplinary approach in managing patients with dual respiratory and cardiovascular compromise undergoing high-risk abdominal surgery [3].

## References

- [1] Moon AS, DeAngelis AM, Fairbairn M, Kulikowski K, Goldenberg D, Chuang L, et al. Removal of 132-pound ovarian mucinous cystadenoma: A case report. *SAGE Open Med Case Rep.* 2020; 8:2050313X20906738
- [2] Matsuo K, Takazawa Y, Yamada Y, Omatsu K, Higashide T, Takiuchi T, et al. Perioperative management of a patient with a giant ovarian tumor. *Medicine (Baltimore).* 2020;99(42):e22676.
- [3] Cai S, Dai R, Mi J, Wang S, Jiang Y. Perioperative management of a patient with a giant ovarian tumor: A case report. *Medicine (Baltimore).* 2020; 99(41):e22625.
- [4] Bamba K, Watanabe T, Kohno T. Anesthetic management of a patient with a giant ovarian tumor containing 83 L of fluid. *Springerplus.* 2013;2:487.