

Incidental Finding of Parasagittal Meningioma Following the Occurrence of Myoclonic Seizure after the Spinal Anesthesia

Azim Honarmand¹, Alireza Hoghooghy^{2*}, Amir Mahabadi³, Mohammad Reza Safavi², Behzad Nazemroaya¹

¹Department of Anesthesiology, Anesthesiology and Critical Care Research Center, Isfahan University of Medical Sciences, Isfahan, Iran.

²Department of Anesthesiology, Isfahan University of Medical Sciences, Isfahan, Iran.

³Department of Neurosurgery, Isfahan University of Medical Sciences, Isfahan, Iran.

ARTICLE INFO

Article history:

Received 22 July 2023

Revised 14 August 2023

Accepted 28 August 2023

Keywords:

Extra-axial brain tumor;

Myoclonic seizure;

Spinal anesthesia

ABSTRACT

In the present manuscript, an 87-year-old man, who was a candidate for knee joint replacement surgery due to severe osteoarthritis of the right knee, was case reported. He underwent neuroaxial anesthesia. Following spinal anesthesia with bupivacaine 0.5% in the fourth and fifth lumbar vertebra, the patient developed myoclonic seizures in the lower limbs and abdomen that lasted during the surgery, as well. Due to the continuation of the seizures, the necessary examinations were performed and an extra-axial tumor in the left parasagittal was detected in the patient's brain imaging.

Introduction

One of the common types of anesthesia usually used in lower limb surgeries is spinal anesthesia which is the preferred type, especially in the elderly or pregnant women due to the prevention of general anesthesia complications [1]. Complications of spinal anesthesia include local complications of lumbar puncture (such as hematoma or collection in this region), infections, systemic complications (such as hypotension or hemodynamic instability) and temporary or permanent spinal cord injuries (such as permanent paraplegia) [2]. However, involuntary myoclonic movements following spinal anesthesia are a very rare complication [3]. Myoclonus has been characterized as the development of any sudden and involuntary contractions in a part of a muscle, an individual muscle, or a muscle group. Spinal myoclonus is distinguished from other generalized myoclonus by a number of features. Generally, it is developed due to some diseases that engage the spinal cord and is limited to a few somatic regions [4-5].

The onset of myoclonus can occur shortly, hours, or days after the spinal cord stimulation. In addition, any spinal stimulus such as tumors, trauma, or degenerative processes can lead to this phenomenon [6]. Among brain tumors, meningiomas are one of the most common intracranial neoplasms and more than half of patients with meningiomas suffer from seizures and involuntary myoclonic movements [7].

Neuraxial movements are different from those of normal myoclonus that have unclear causes [8] so more case reports should be provided to increase awareness in this regard and determine the etiology of these symptoms and distinguish spinal myoclonic from other myoclonic movements. Therefore, the present article reported a case of an incidental identification of parasagittal meningioma following the occurrence of myoclonic seizures during spinal anesthesia with bupivacaine.

Case Report

The patient, an 87-year-old man with a height of 168 cm and a weight of 75 kg, was admitted for knee

The authors declare no conflicts of interest.

*Corresponding author.

E-mail address: alirezaa.hoghooghy@med.mui.ac.ir

Copyright © 2024 Tehran University of Medical Sciences. Published by Tehran University of Medical Sciences.



This work is licensed under a Creative Commons Attribution-NonCommercial 4.0 International license (<https://creativecommons.org/licenses/by-nc/4.0/>). Noncommercial uses of the work are permitted, provided the original work is properly cited.

replacement surgery. In the pre-operative examination, the patient had a history of controlled diabetes and blood pressure. Vital signs were stable, and he did not mention the history of surgery or anesthesia. Neurological examinations were normal. After obtaining the patient's consent and exchanging opinions with the surgical team, the patient became a candidate for spinal anesthesia. Three ml of isobaric Marcaine 0.5% plus 25 micrograms of fentanyl was used to the spinal anesthesia in the L4-L5 space with a needle spinal Whitacre (size 23).

After performing the anesthesia and patient's lying down, he felt nausea and vomiting. He spontaneously was recovered after few minute. Vital signs were stable during vomiting. Ten minutes after the anesthesia, the sensory level were fixed using the pinprick test in the T10 level. Moreover, the Bromage score was 1. The patient was delivered to the orthopedic team. About 15 minutes after the start of anesthesia and during the surgery, the myoclonic movements of the left lower limbs and abdomen started with a low frequency and reached about 20 movements per minute after a few minutes.

Due to the interference of these movements with surgery and that these movements were benign, the patient was treated with a sedative dose of propofol (25 µg/kg/min) and these movements were controlled. During the surgery, no significant pathological and uncontrolled findings occurred. At the end of the surgery,

the frequency of movements was restored after two hours, and the dose of propofol was increased from 50 to 70 µg/kg/min. The patient's movements started again and reached a frequency of 20 movements per minute at the end of the surgery after discontinuing propofol and transferring the patient to PACU. Midazolam 2 mg was prescribed although it made no difference.

The patient was examined by a neurologist. No pathological findings were found except myoclonus movements of the left lower limb and abdomen (the left hand had no movements).

A brain CT scan was requested. In the performed CT scan, an extra-axial brain tumor with the suspicion of meningioma was reported in the right part of the frontal lobe (Figure 1).

According to the above-mentioned conditions, the patient was treated with 3.5 g of levetiracetam bolus and then 1 g three times a day.

The patient was transferred to the ICU, and his myoclonic movements began to decrease and stopped after six hours. After three days, the patient was discharged with orthoped order, continued treatment with levetiracetam three times a day without having any myoclonic movements and neurological symptoms, and was referred to the neurosurgery team for follow-up and treatment of meningioma.

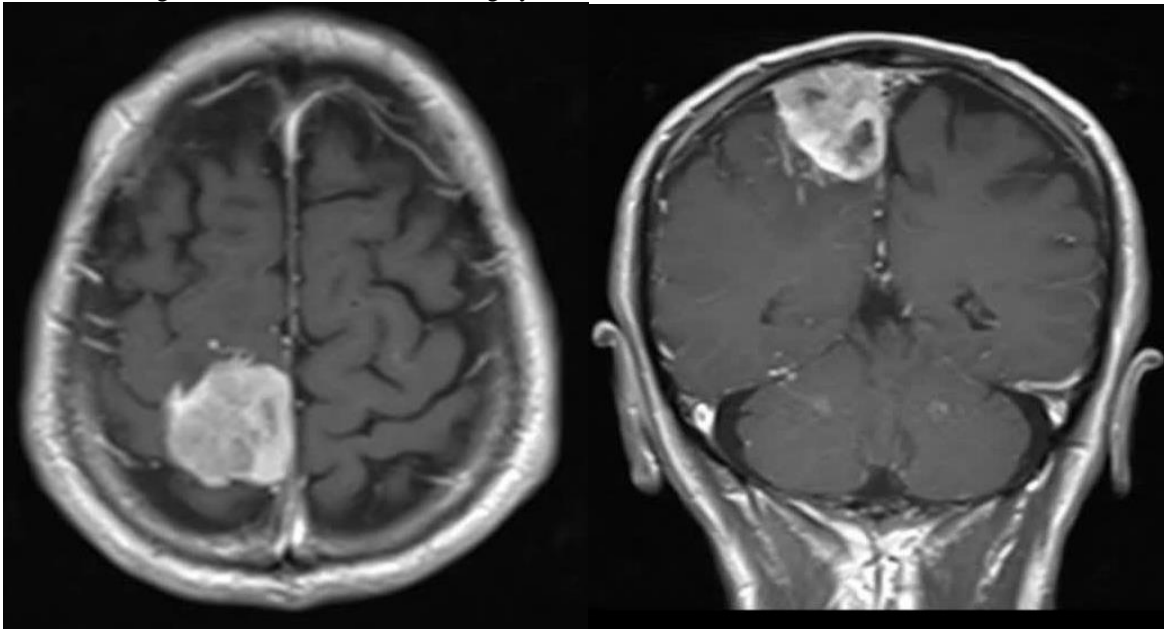


Figure 1- Brain CT scan

Discussion

Spinal myoclonus is a reaction to a stimulus in a specific region of the spinal cord. The contractions caused by this complication are usually repetitive, limited to one muscle or a group of muscles, and appear at different time intervals. This type of myoclonus is not affected by sleep, anesthesia, or coma [4]. The

pathophysiology of spinal myoclonus seems to be the abnormal hyperactivity of the local dorsal horn interneurons, with the loss of the inhibition of the descending supra-segmental pathways [9].

Approximately 15 minutes after the onset of spinal anesthesia, the reported case had low-frequency myoclonic movements of the left lower limb and abdomen that increased over time.

Batra et al. reported a case of spinal myoclonus in a healthy 45-day-old infant immediately after intrathecal injection of bupivacaine and fentanyl [10]. Abrão et al. also reported a 63-year-old patient with ASA I that was a candidate for transurethral resection of the prostate. After subarachnoid anesthesia with bupivacaine (15 mg), he had involuntary tonic-clonic movements of the lower limbs during surgery [11]. Similarly, Budi et al. reported a 22-year-old female candidate for skin graft surgery that underwent spinal anesthesia with hyperbaric bupivacaine 0.5% (12 mg). Ten minutes after the surgery, she experienced bilateral involuntary myoclonic movements of the upper limbs during recovery [12]. As it can be noticed, although this complication is very rare and more common in people over 60 years old, its occurrence has been reported in different age groups. In line with the present study, the aforementioned studies reported the successful intravenous injection of midazolam in controlling spinal myoclonic movements [10-12]. Some myoclonus, such as propriospinal myoclonus, can last for several days or months and are less responsive to medications. The most commonly used drugs in this case are benzodiazepines (clonazepam and diazepam), sodium valproate, carbamazepine, and levetiracetam [13].

Spinal cord irritation may be induced by local anesthesia and result in repetitive and spontaneous discharges of the groups of anterior horn cells. Some studies have proposed that the role of bupivacaine in inhibitory neurons may not only result in the inhibitory function loss in the spinal cord but also heighten the alpha motor neuron irritability, causing myoclonus [14, 3].

Since our patient did not have a history of any special diseases, had unremarkable neurological and laboratory findings, and had no previous history of drug sensitivity, it was initially assumed that it could be one of the complications of spinal anesthesia with bupivacaine, so that myoclonus movements were controlled by administering propofol. However, myoclonic movements started again in the reported case after surgery (during recovery). Moreover, their frequency increased so that despite the administration of midazolam 2 mg, there was no decrease in the intensity of these movements. Therefore, its origin was attributed to other causes. According to the brain CT scan, extra-axial tumor with meningioma was seen in the right part of the frontal lobe. Therefore, 3.5 g of levetiracetam was prescribed for this patient, and these movements were stopped after 6 hours.

It seems that the stimulation of the motor cortex caused by the outflow of cerebrospinal fluid and the effect of pressure caused by the extra-axial tumor were effective in the occurrence of seizure symptoms [15]. Probably due to the stimulation of the motor cortex, convulsive actions were formed in this part of the brain and generated a focal myoclonic seizure attack. The EEG and the control of the patient's symptoms by starting and continuing anticonvulsant treatment confirmed the mentioned point.

On the other hand, despite the presence of an intracranial space-occupying mass, no symptoms of brain herniation or generalized seizures were observed in this patient due to atrophy caused by old age.

Conclusion

During spinal anesthesia we should consider abnormal movement and use of anticonvulsant drug and neurologic imaging as needed.

References

- [1] Lee JH, Yoon DH, Heo BH. Incidence of newly developed postoperative low back pain with median versus paramedian approach for spinal anesthesia. *Korean J Anesthesiol.* 2020;73(6):518-24.
- [2] De Tommaso O, Caporuscio A, Tagariello V. Neurological complications following central neuraxial blocks: are there predictive factors? *Eur J Anaesthesiol.* 2002;19(10):705-16.
- [3] Shiratori T, Hotta K, Satoh M. Spinal myoclonus following neuraxial anesthesia: a literature review. *J Anesth.* 2019; 33(1):140-7.
- [4] Celik Y, Demirel CB, Karaca S, Kose Y. Transient segmental spinal myoclonus due to spinal anaesthesia with bupivacaine. *J Postgrad Med.* 2003; 49(3):286-7.
- [5] Caviness JN. Myoclonus. *Continuum: Lifelong learning in neurology.* 2019;25(4):1055-80.
- [6] Hoss C. Anesthetic Implications for Patients with Friedreich's Ataxia. 2019.
- [7] Zouaoui S, Darlix A, Rigau V, Mathieu-Daudé H, Bauchet F, Bessaoud F, et al. Descriptive epidemiology of 13,038 newly diagnosed and histologically confirmed meningiomas in France: 2006–2010. *Neurochirurgie.* 2018; 64(1):15-21.
- [8] Moen V, Dahlgren N, Irestedt L. Severe neurological complications after central neuraxial blockades in Sweden 1990–1999. *Anesthesiology.* 2004; 101(4):950-9.
- [9] Cassim F, Houdayer E. Neurophysiology of myoclonus. *Neurophysiologie Clinique/Clinical Neurophysiology.* 2006; 36(5-6):281-91.
- [10] Batra YK, Rajeev S, Lokesh VC, Rao KL. Spinal myoclonus associated with intrathecal bupivacaine and fentanyl in an infant. *Can J Anaesth.* 2007; 54:587-8.
- [11] Abrão J, de Paula Bianco M, Roma W, de Souza Krippa JE, Hallak JE. Spinal myoclonus after subarachnoid anesthesia with bupivacaine. *Rev Bras Anesthesiol.* 2011; 61(5):619-23.
- [12] Budi V, Manohar N, Fultambkar G, Srinivasaiah B. Propriospinal myoclonus following spinal anesthesia: A rare complication. *J Anaesthesiol Clin Pharmacol.* 2019; 35(2):273-4.
- [13] Caviness JN, Brown P. Myoclonus: current concepts and recent advances. *Lancet Neurol.* 2004;

- 3(10):598-607.
- [14] Zamidei L, Bandini M, Michelagnoli G, Campostrini R, Consales G. Propriospinal myoclonus following intrathecal bupivacaine in hip surgery: a case report. *Minerva Anesthesiol.* 2009; 76(4):290-3.
- [15] Alonso R, Pisa D, Marina AI, Morato E, Rábano A, Rodal I, et al. Evidence for fungal infection in cerebrospinal fluid and brain tissue from patients with amyotrophic lateral sclerosis. *Int J Biol Sci.* 2015;11(5):546.