

Anaesthetic Management of Pediatric Patient with Osteogenesis Imperfecta Posted for Radius Ulna Nailing: A Case Report

Jyoti Deshpande^{1*}, Shreya Rajendra Rawekar²

¹Department of Anesthesiology, SMCW, Symbiosis International University, Pune, India.

²Department of Anesthesiology, Smt.Kashibai Navale Medical College and General Hospital, Pune, Maharashtra, India.

ARTICLE INFO

Article history:

Received 06 July 2022

Revised 27 July 2022

Accepted 12 August 2022

Keywords:

Osteogenesis imperfecta;

Total intravenous anaesthesia;

Ultrasonography;

Supraclavicular brachial plexus

block

ABSTRACT

Osteogenesis imperfecta is a collagen disorder of autosomal dominant type caused by mutation of type COLIA-1 and COLIA-2 genes. Orthopaedic surgery in paediatric patient patients of OI is challenging mainly due to difficult airway and risk of malignant hyperthermia. Here we report, a paediatric case of OI with similar family history posted for radius ulna nailing which was managed with total intravenous anaesthesia and supraclavicular brachial plexus block.

Introduction

Osteogenesis imperfecta (OI) which is also known as brittle bone disease. It is caused by mutation of collagen type COLIA-1 and COLIA-2 genes [1]. The diagnosis of osteogenesis imperfecta (OI) is usually made on the basis of family history, genetic testing and clinical characteristics such as osteoporosis, skeletal deformity, blue sclera, brittle bones, coagulopathy, defective dentition and cranio-vertebral junction anomalies. OI potentiates the risk of hemorrhages and iatrogenic fractures [1-2]. Therefore, orthopedic surgery in pediatric patients of OI poses substantial challenge for the anesthesiologist. Here, we report a pediatric case of OI with multiple fractures caused by minor trauma. We obtained informed written consent by caregiver and have reported this case according to CARE guidelines.

Case Report

A 6yr old female, 1st product of non-consanguineous marriage, presented to anesthesia OPD with right midshaft radius ulna fracture, posted for closed reduction internal fixation with TENS. Patient was a diagnosed case of OI with history of recurrent fractures since birth which were managed conservatively with casting.

Patient had history of 1 episode of tonic-clonic seizure 2 months prior with clenching of jaw lasting for 10 secs, associated with uncontrollable jerky movements of arms and legs with staring spell, loss of consciousness, muscle stiffness and voiding of urine. Following which patient was taken to the hospital given some treatment for which details are not available, but thereafter no regular treatment was required.

Patient had history of bilateral tibia fractures at 2.5yrs of age due to trivial trauma while playing. First on right side, followed by left side which was managed with casting. Patient had a full term normal vaginal delivery

The authors declare no conflicts of interest.

*Corresponding author.

E-mail address: jyotim16@gmail.com

Copyright © 2023 Tehran University of Medical Sciences. Published by Tehran University of Medical Sciences.



This work is licensed under a Creative Commons Attribution-NonCommercial 4.0 International license (<https://creativecommons.org/licenses/by-nc/4.0/>). Noncommercial uses of the work are permitted, provided the original work is properly cited.

with no history of NICU admission. There was no history of developmental delay, and all the milestones were achieved according to age. There was a similar history of multiple fractures requiring operative management in her mother and grandmother, suggestive of similar illness in the family.

On examination patient was averagely built, weighing 20kg with typical feature of blue sclera. Her heart rate was 122/min and blood pressure 92/58 mmhg. There was no pallor, icterus, cyanosis, clubbing, lymphadenopathy, pedal oedema, kyphoscoliosis, hearing loss. Airway assessment showed normal flexion and extension of neck with adequate mouth opening and normal dentition, Mallampatti class II. The respiratory, cardiac and central nervous system examination was not suggestive of any abnormalities.

Routine hemogram, coagulation profile, liver function test, renal function test was normal. For cardiac screening, ECG, chest X-ray and 2D-echo was done. No abnormalities were detected. The patient was accepted for surgery under American society of anesthesiologists grade III.

Our plan of anesthesia was LMA insertion with regional block technique. Thorough operating room preparation was done including difficult airway equipment, cardiac drugs and measures were taken to deal with hypothermia if any. (Bear hugger and fluid warmer)

After informed written high risk consent taken from guardian and confirming the NBM status. The patient was taken inside the OT. The patient was positioned very carefully on the operation table and pressure points were padded adequately. ASA standard monitors including ECG, NIBP, SpO₂ probe. The temperature probe was inserted rectally. Adequate padding was done before placing the blood pressure cuff and the interval was set for 20 mins and was taken in between when needed.

Her baseline blood pressure was 98/60mmHg, heart rate was 138/min, and oxygen saturation on room air was 98%. An intravenous (IV) preload with 0.45% DNS was done according to weight and Nil by mouth (NBM) hours. Patient was preoxygenated with 100% O₂ for 3 mins with Jackson Rees (JR) circuit and premedicated with inj. Glycopyrrolate 80 mcg IV+ Inj. Midazolam 0.6mg IV+ Inj. Emset 1.6 mg IV+ Inj. Fentanyl 40mcg IV. After complete relaxation I-gel LMA 2.0 was inserted. Air entry confirmed with chest rise, on auscultation and with help of end tidal CO₂. Patient was maintained with 50% O₂+50%Air on JR circuit, and inj. Propofol.

After proper positioning, under all aseptic precaution ultrasound guided supraclavicular brachial plexus block was given with given inj. Ropivacaine 0.2% 8cc after negative aspiration.

Tourniquet was avoided during the surgery, as it increases the chances of iatrogenic fractures. Blood loss was minimal. Operation lasted for 54 mins. LMA was removed after the complete awakening of patient post-operatively. Surgery went uneventful. Analgesia lasted

for 320 mins post operatively after which patient received rescue analgesia inj. Paracetamol 300mg IV. There were no observed post-operative complications. Patient was discharged on POD3. Routine follow-up was done after a week in orthopedic OPD.

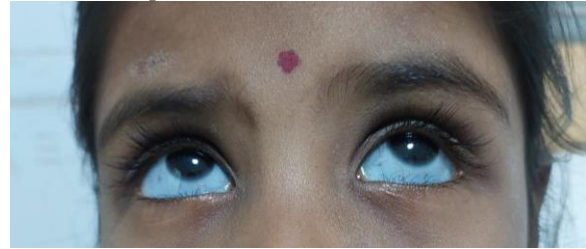

Figure 1- Blue sclera

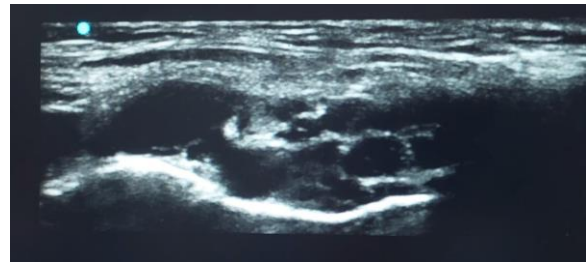


Figure 2- Supraclavicular plexus

Discussion

OI is a rare genetic disorder (1:20,000) which is due to lack of type I collagen (found in bones, ligaments, and teeth). As a result of gene mutation (X- linked recessive pattern- it is an autosomal recessive pattern of inheritance), the body may not make enough collagen and bones may weaken [1].

OI symptoms include:

- Bone deformity and pain
- Easy bruising
- Difficulty in breathing
- Loose joints or muscle weakness
- Curved spine
- Weak, brittle or discoloured teeth

To confirm an OI diagnosis after a baby is born, healthcare provider may use blood test to check for gene mutation that indicates brittle bone disease. Bone density test (DEXA scan) using low dose x-rays across the body to measure mineral levels in bone [2]. Anaesthetic management of OI is prejudiced by diversity of presentation, such as co-existing orthopaedic deformities, fragile bone prone for fractures at the time of positioning, platelet dysfunction, cardiovascular abnormalities such as mitral valve prolapse, tendency to develop malignant hyperthermia, anticipated difficult intubation because of abnormal cervical spine mobility, fragile teeth, odontaxial dislocation and risk of mandibular and facial fractures [2].

An automated non-invasive blood pressure (NIBP) cuff is perilous as overinflation may result in fractures. Therefore, invasive or manual sphygmo-manometer or NIBP with longer duration should be used. All pressure points should be well padded. Thorough pre operative routine workup along with cardiorespiratory workup including echocardiography and pulmonary function test should be done.

There have been several case reports managing such cases under general anesthesia. Karabiyik et al. recommended total intravenous anesthesia (TIVA) along with intubating LMA [3-4]. As a result of increased risk of odonto axial dislocation endotracheal intubation should be avoided [4]. Spinal and chest wall deformities may incline patients towards pulmonary disease, ventilation perfusion mismatch and rapid desaturation. Pectus carinatum and kyphoscoliosis restrain thoracic movement and lung expansion causing restrictive pulmonary disease which leads to decreased vital capacity, decreased FRC, decreased chest wall compliance.

Succinylcholine should be avoided due to possible risk for fasciculation induced fractures and malignant hyperthermia [5]. Porsbog et. Al stated that metabolic acidosis and malignant hyperthermia had developed following general anesthesia using barbiturate, fentanyl, pancuronium and nitrous oxide in patients with osteogenesis imperfecta [5-6]. It is also recommended that triggering drugs such as volatile anesthetic's, succinylcholine, anticholinergic agents and ondansetron should be avoided. In order to avoid the development of malignant hyperthermia intra-operatively total intravenous anesthesia is recommended [7]. Furderer et. al also recommended TIVA + enflurane anesthesia as he found lower body temperature intra and post operatively and he also recommended TIVA with propofol [7].

Santos et. al stated that there was no significant rise in body temperature and hemodynamic stability was provided with sevoflurane in patients with OI [8]. Therefore, we decided insertion of LMA under propofol and maintenance on TIVA with inj. Propofol and Brachial plexus block with supraclavicular approach for analgesia. Temperature monitoring was done intra and post operatively.

Regional anesthesia is recommended in patients with OI as it avoids need for tracheal intubation. Henceforth, before regional anesthesia coagulation profile should be done due to risk of increase bleeding time in spite of normal platelet count. Regional anesthesia has several recompenses by providing intra-op as well as post op analgesia and lesser requirement of intravenous and inhalational agent.

Conclusion

Careful preoperative evaluation, appropriate planning with major emphasis on the difficult airway management, selection of techniques and drugs to avoid deleterious complication like malignant hyperthermia as well as utmost care of positioning are necessary factors for providing safe anesthesia in OI.

We hope that our case report will encourage skilled anesthesiologists to administer regional anesthesia technique and to provide quality care for OI patients.

Abbreviations

OI- Osteogenesis imperfecta USG: Ultrasonography, SCB- Supra clavicular block TIVA- Total intravenous anesthesia LMA- Laryngeal mask airway NIBP- Non-invasive blood pressure NBM- Nill by mouth ASA- American society of anesthesiology

References

- [1] Bissonnette B, Luginbuehl I, Marciniak B, Dalens B. Osteogenesis Imperfekta, Syndromes. 1st ed. New York: McGraw-Hill Medical Publishing Division. 2005;618-621.
- [2] Baum VC, O'Flaherty JE. Anesthesia for Genetic, Metabolic, and Dysmorphic Syndromes of Childhood. 2nd Edition Lippincott Williams & Wilkins. 2007; 283-285.
- [3] Karabiyik L, Parpu M, Kurtipek O. Total intravenous anaesthesia and the use of an intubating laryngeal mask in a patient with osteogenesis imperfecta. Acta Anaesthesiol Scand. 2002; 46:618-9.
- [4] Kostopanagiotou G, Coussi T, Tsaroucha N, Voros D. Anaesthesia using a laryngeal mask airway in a patient with osteogenesis imperfecta. Anaesthesia. 2000; 55:506.
- [5] Porsborg P, Astrup G, Bendixen D, Lund AM, Ording H. Osteogenesis imperfekta and malingnant hyperthermia. Is there a relationship? Anaesthesia. 1996; 51:863-865.
- [6] Ogawa S, Okutani R, Suehiro K. Anesthetic management using total intravenous anaesthesia with remifentanil in a child with osteogenesis imperfecta. J Anesth. 2009; 23:123-125.
- [7] Fulderer S, Stanek A, Karbowski A, Eckardt A. Intraoperative hyperpyrexia in patients with osteogenesis imperfecta. Z Ortho Grenzgeb. 2000; 138:136-139.
- [8] Santos ML, Anez C, Fuentes A, Mendez B, Perinan R, Rull M. Airway management with ProSeal LMA in a patient with osteogenesis imperfecta. Anesth Analg. 2006; 103:794.